

Received: 29 January 2025 / Accepted: 30 April 2025 / Published online: 30 June 2025

DOI 10.34689/SH.2025.27.3.015

UDC 616-036.21

This work is licensed under a
Creative Commons Attribution 4.0
International License

SURGICAL TREATMENT OF LEGG-CALVE-PERTHES DISEASE IN CHILDREN

Nazym A. Tuktiyeva¹, <https://orcid.org/0000-0002-4024-6705>**Bolatbek A. Dossanov²**, <https://orcid.org/0000-0001-9816-7404>**Yersin T. Zhunussov³**, <https://orcid.org/0000-0002-1182-5257>**Gapsamet M. Abdulvakhabov¹** <https://orcid.org/0009-0004-1097-8202>¹ NCJSC «Semey Medical University», Department of Traumatology and Pediatric Surgery, Semey, Republic of Kazakhstan;² NCJSC «Astana Medical University», Department of Pediatric Surgery, Astana, Republic of Kazakhstan;³ International Science Center of Traumatology and Orthopedics. Almaty. Republic of Kazakhstan.

Abstract

Introduction. Legg-Calve-Perthes disease is an idiopathic aseptic avascular osteonecrosis of the epiphysis of the femoral bone head. The age of diagnosis of the disease is usually between 4 and 12 years-old age, with an average of 6 years-old age. The course and prognosis of Perthes disease is difficult to predict. The prognosis of the disease depends on the age of the child, on the site of damage to the epiphysis of the femoral head, on the level of the destroyed height of the lateral column of the pineal gland.

Materials and methods. The study design is a prospective controlled clinical trial. From 2018 to 2022, 10 children with Legg-Calve-Perthes disease were operated. Under general anesthesia, the patient underwent hardware unloading of the hip joint under X-ray control. The age of the patients ranged from 7 to 11 years-old, 9 cases were boys, 1 case was a girl and all cases were one-sided. The duration of treatment in the device ranged from 28 to 39 days. Radiologically, the severity of the disease and the indications for surgery were set according to the classifications of Salter-Thomson and Catterall.

Results The follow-up period ranged from 6 months to 4 years, with an average of 2 years. A total of 10 patients (9 boys and 1 girl) were enrolled in this study. The median age at symptom onset was 8.3 years-old (range 7–11 years-old) and the median age of having surgery was 9.1 years-old (range 7–11 years-old). Five cases are right-sided hip lesions, the remaining five are left-sided hip lesions. In the present study, there was not a single case of bilateral hip lesion. At the time of surgery, two patients had 2nd stage of the disease, eight patients had 3rd stage of the disease (20% in the second stage of the disease, 80% in the third stage). Distraction was performed over an average of 14 days (range 10-17 days). The median duration of AEF wearing was 30.6 days (range 28–39 days).

Conclusions. Hardware unloading of the hip joint is currently a promising treatment for Legg-Calve-Perthes disease, which has a future. This method of treatment has advantages such as simplicity of technique, minimal complication rate, short period of hospitalization, correction of shortening, since it increases the length of the limb, shorten the recovery time of the femoral head. Providing radiographic sphericity of the femoral head improves the range of motion of the hip joint.

Key words: Legg-Calve-Perthes disease, hardware unloading, epiphyseal index, Modified Harris Hip score, Stulberg classification.

For citation:

Tuktiyeva N.A., Dossanov B.A., Zhunussov Ye.T., Abdulvakhabov G.M. Surgical treatment of Legg-Calve-Perthes disease in children // *Nauka i Zdravookhranenie* [Science & Healthcare]. 2025. Vol.27 (3), pp. 135-142. doi 10.34689/SH.2025.27.3.015

Резюме

ХИРУРГИЧЕСКОЕ ЛЕЧЕНИЕ БОЛЕЗНИ ЛЕГГ-КАЛЬВЕ-ПЕРТЕСА У ДЕТЕЙ

Назым А. Туктиева¹, <https://orcid.org/0000-0002-4024-6705>**Болатбек А. Досанов²**, <https://orcid.org/0000-0001-9816-7404>**Ерсын Т. Жунусов³**, <https://orcid.org/0000-0002-1182-5257>**Гапсамет М. Абдулвахабов¹** <https://orcid.org/0009-0004-1097-8202>¹ НАО «Медицинский университет Семей», Кафедра травматологии и детской хирургии, г. Семей, Республика Казахстан;² НАО «Медицинский университет Астана», Кафедра детской хирургии, г. Астана, Республика Казахстан;³ Международный научный Центр Травматологии и Ортопедии, г. Алматы, Республика Казахстан.

Введение. Болезнь Легга-Кальве-Пертеса это идиопатический асептический аваскулярный остеонекроз эпифиза головки бедренной кости. Возраст постановки диагноза заболевания обычно составляет от 4 до 12 лет, среднем в 6

лет. Течение и прогноз болезни Пертеса тяжело предсказать. Прогноз заболевания зависит от возраста ребенка, от участка поражения эпифиза головки бедра, от уровня разрушенной высоты латерального столба эпифиза.

Материалы и методы. Дизайном исследования является проспективное контролируемое клиническое исследование. С 2018 года по 2022 год в было прооперировано 10 детей с заболеванием Легг-Кальве-Пертеса. В условиях общей анестезии пациенту выполнялся аппаратная разгрузка тазобедренного сустава под рентгенологическим контролем. Возраст пациентов варьировался от 7 до 11 лет, 9 случаев мальчики, 1 случай девочка и все случаи были односторонними. Продолжительность лечения в аппарате варьировалось от 28 до 39 дней. Рентгенологически тяжесть заболевания и показания к операции выставляли по классификациям Солтера-Томсона и Каттералла.

Результаты. Период наблюдения составлял от 6 месяцев до 4 лет, в среднем 2 года. В общей сложности в это исследование были включены 10 пациентов (9 мальчиков и 1 девочка). Средний возраст на момент появления симптомов составлял 8,3 года (диапазон 7–11 лет), а средний возраст на момент операции составлял 9,1 лет (диапазон 7–11 лет). Пять случаев правостороннее поражение тазобедренного сустава, остальные пять - левостороннее поражение тазобедренного сустава. В настоящем исследовании не было ни одного случая с двусторонним поражением тазобедренного сустава. На момент операции у двоих пациентов было 2 степень заболевания, у восьмерых 3 стадия заболевания (20% на второй стадии заболевания, 80% на третьей стадии). Дистракция проводилась в среднем в течение 14 дней (диапазон 10-17 дней). Средняя продолжительность ношения АВФ составила 30,6 дней (диапазон 28–39 дней).

Выводы. Аппаратная разгрузка тазобедренного сустава в настоящее время является перспективным методом лечения болезни Легга-Кальве-Пертеса, у которого есть будущее. Этот метод лечения имеет преимущества, как простота техники, минимальная частота осложнений, короткий период госпитализации, коррекция укорочения, поскольку оно увеличивает длину конечности, сократит сроки восстановления головки бедра. Обеспечивая рентгенографическую сферичность головки бедренной кости улучшает диапазон движения тазобедренного сустава.

Ключевые слова: болезнь Легга-Кальве-Пертеса, аппаратная разгрузка, эпифизарный индекс, Modified Harris Hip score, классификация по Stulberg.

Для цитирования:

Туктеева Н.А., Досанов Б.А., Жунусов Е.Т., Абдулвахабов Г.М. Хирургическое лечение болезни Легг-Кальве-Пертеса у детей // Наука и Здравоохранение. 2025. Т.27 (3), С. 135-142. doi: 10.34689/SH.2025.27.3.015

Түйіндеме

БАЛАЛАРДАҒЫ ЛЕГГ-КАЛЬВЕ-ПЕРТЕС АУРУЫНЫҢ ХИРУРГИЯЛЫҚ ЕМІ

Назым А. Туктеева¹, <https://orcid.org/0000-0002-4024-6705>

Болатбек А. Досанов², <https://orcid.org/0000-0001-9816-7404>

Ерсын Т. Жунусов³, <https://orcid.org/0000-0002-1182-5257>

Гапсамет М. Абдулвахабов¹ <https://orcid.org/0009-0004-1097-8202>

¹ «Семей медицина университеті» КЕАҚ, Травматология және балалар хирургиясы кафедрасы, Семей қ., Қазақстан Республикасы;

² «Астана медицина Университеті» КЕАҚ, Балалар хирургиясы кафедрасы, Астана қ., Қазақстан Республикасы;

³ Халықаралық травматология және ортопедия ғылыми орталығы. Алматы қ., Қазақстан Республикасы.

Кіріспе. Легг-Кальве-Пертес ауруы — бұл жамбас сүйегінің басының эпифизінің идиопатиялық асептикалық аваскулярлық остеонекрозы. Диагноз негізінен 4-тен 12 дейінгі жаста, көбінесе 6 жаста қойылады. Аурудың ағымы мен болжамы баланың жасына, жамбас сүйегі басының эпифизінің зақымданған аймағына және эпифиздің бүйір бағанының биіктігінің бұзылу деңгейіне байланысты.

Материалдар мен әдістер. Зерттеу дизайны проспективті бақыланатын клиникалық зерттеу болып табылады. 2018-2022 жылдар аралығында Легг-Кальве-Пертес ауруымен 10 балаға ота жасалды. Жалпы анестезия жағдайында пациентке жамбас буынын рентген бақылауымен аппараттық жеңілдету жүргізілді. Пациенттердің жасы 7-ден 11 жасқа дейін, 9 ұл және 1 қыз болды, барлық жағдайлар біржақты болды. Аппаратта емдеу ұзақтығы 28-ден 39 күнге дейін өзгерді. Аурудың ауырлығын және операция көрсеткіштерін рентген арқылы Salter-Thompson және Catterall классификациялары бойынша анықтады.

Нәтижелер. Бақылау кезеңі 6 айдан 4 жылға дейін, орта есеппен 2 жылды құрады. Зерттеуге 10 пациент (9 ұл және 1 қыз) енгізілді. Симптомдардың пайда болған сәтіндегі орташа жас 8,3 жасты (7–11 жас), ал ота жасалған сәттегі орташа жас 9,1 жасты (7–11 жас) құрады. Бес жағдайда оң жақ жамбас буыны, қалған бесеуінде сол жақ жамбас буыны зақымдалды. Зерттеуде екі жақты зақымдалу жағдайлары тіркелген жоқ. Ота кезінде екі пациентте аурудың 2 сатысы, сегіз пациентте 3 сатысы анықталды (20% — 2-саты, 80% — 3-саты). Орташа дистракция кезеңі 14 күн (10-17 күн), ал аппаратты кию ұзақтығы орта есеппен 30,6 күн (28–39 күн) болды.

Қорытынды. Жамбас буынын аппараттық жеңілдету қазіргі уақытта Легг-Кальве-Пертес ауруын емдеудің болашағы зор әдісі болып табылады. Бұл әдістің техникасының қарапайымдылығы, асқынулардың минималды жиілігі, қысқа ауруханада болу кезеңі, аяқтың ұзындығын арттыра отырып, қысқаруды түзету сияқты артықшылықтары бар. Жамбас

басының қалпына келу уақытын қысқартады және рентгенологиялық түрде эпифиз басының сфералық формасын сақтауды қамтамасыз етеді, бұл жамбас буынының қозғалыс диапазонын жақсартады.

Түйінді сөздер: *Легг-Кальве-Пертес ауруы, аппараттық жеңілдету, эпифизарлық индекс, Modified Harris.*

Дәйексөз үшін:

Туктеева Н.А., Досанов Б.А., Жунусов Е.Т., Абдулвахабов Г.М. Легг-Кальве-Пертес ауруының хирургиялық емі // Ғылым және Денсаулық. 2025. Т.27 (3), Б. 135-142. doi: 10.34689/SH.2025.27.3.015

Introduction

Legg-Calve-Perthes disease is an idiopathic aseptic avascular osteonecrosis of the epiphysis of the femoral head [1]. The age of diagnosis of the disease is usually between 4 and 12 years-old age, with an average of 6 years-old age. The course and prognosis of Perthes disease is difficult to predict. The prognosis of the disease depends on the age of the child, on the site of the lesion of the epiphysis of the femoral head, on the level of the destroyed height of the lateral column of the pineal gland [2]. The prognosis of the disease assesses the sphericity of the femoral head and the congruence of the hip joint, the height of the lateral column of the epiphysis, that is, the height of the femoral head and the range of motion of the hip joint [3]. In our study, most patients were treated in the later stages of the disease and children older than 7-8 years, when there is already an insufficient range of motion of the hip. In the worst development of the disease, this condition can lead to degenerative osteoarthritis in childhood.

The explanations for this fact lie in the fact that the acetabulum is not able to adapt to the congruence of the deformed femoral head due to a decrease in the elasticity of the acetabulum [4], there is less time for growth and remodeling of the femoral head [5].

The method of treating Perthes disease in the age categories above 7 years causes a lot of controversy. The main principles of treatment have traditionally been to lighten the load and unload the femoral head [6]. Various surgical treatment options have been proposed, but they have some inherent drawbacks. Osteotomy of the femur with varus rearrangement can even increase the mismatch of the hip, as well as shorten the limb [7]. Valgus osteotomy of the femur can lead to unloading of the deformed head, but it can increase the lateral subluxation of the femoral head [8]. None of these procedures affect the underlying avascular process of the femoral head. The acetabulum lateral shelf procedure [9], Salter's osteotomy [10], Chiari's osteotomy [11], and triple osteotomy [12] aim to change the orientation or increase the size of the acetabulum and provide greater support for the femoral head. However, these approaches do not reduce the pressure on the femoral head or change the shape of the femoral head. No conventional treatment has shown any statistically significant efficacy in improving the outcome of Perthes disease.

Distraction of the hip joint with the help of an external fixation apparatus of the Ilizarov type is a relatively new method of treating Perthes disease. The concept of this method of treatment is that by creating space in the joint and removing the load on the articular surface, synovial circulation improves. It contributes to the fibrous restoration of articular cartilage defects and additionally preserves the intact part of the femoral head [13]. We present our results from this prospective study to evaluate the effect of hip relief on a selected group of patients over 7 years of age with Perthes disease.

For a long time, it was not clear why some patients have minimal clinical and radiological manifestations with a quick recovery, while others have a pronounced picture of pathology with a long course of the disease and a poor outcome. Various classifications were proposed, which to some extent made it possible to predict the final result of the course of the disease. According to these classifications, the outcome of the disease depends on the volume (degree) of damage to the head. That is, the more the head is affected, the worse the outcome of the disease will be. In our study, the indications for surgery were set according to the classifications of Salter-Thomson [14] and Catterall [15]. The Catterall classification was proposed in 1971 in order to clarify the indications for various types of treatment and to provide an early prediction of the course of the disease.

The classification is based on X-ray examination data in the fragmentation stage

Type I: less than 25% involvement.

Type II: 50% involvement, the lateral part is static.

Type III: 75% involvement, collapse of the lateral part of the head.

Type IV: full involvement.

The Salter-Thompson classification was proposed in 1984 for the prediction and selection of treatment. It is based on determining the length of the subchondral fracture site. The authors believe that the development of the disease depends solely on the degree of damage to the femoral head in the early stages and distinguish only two groups: group A: less than 50% involvement of the width of the femoral head, group B: more than 50% involvement.

The aim of the study was to evaluate the results of surgical treatment of Legg-Calve-Perthes disease in children.

Materials and methods.

The study design is a prospective controlled clinical trial. There is an informed consent of the patient's parents for the interventions and further description in the publications of the results of treatment. Informed consent was signed by all parents of the children involved prior to the start of the study. They were informed that participation was voluntary and could opt out at any time. None of them received anything in return for their participation. The management of the clinic is aware of the interventions carried out and does not object to the issue of covering the results in the open press. The study is approved by the Ethics Committee from Protocol No. 2 of 25.10.2018 and the research is carried out within the framework of a doctoral dissertation. The study was conducted in accordance with the principles of the Declaration of Helsinki.

From 2018 to 2022, 10 children with Legg-Calve-Perthes disease were operated on in our institution.

The inclusion criteria were as follows:

1. Age over 7 years-old.
2. Perthes disease at stages 2, 3 of the disease.
3. Strong traffic restriction.
4. Pain.

The age of the patients ranged from 7 to 11 years-old, 9 cases were boys, 1 case was a girl and all cases were one-sided.

Quantitative variables did not obey the law of normal distribution. The Wilcoxon criterion was applied.

Operational equipment

Under conditions of general anesthesia, the patient underwent unloading of the hip joint under X-ray control. The surgical intervention included the installation of a rod apparatus

for external fixation using the technology developed by us (patent No. 5386, 2021 was obtained), the correct dosed distraction system, using telescopic rods. Figure 1.

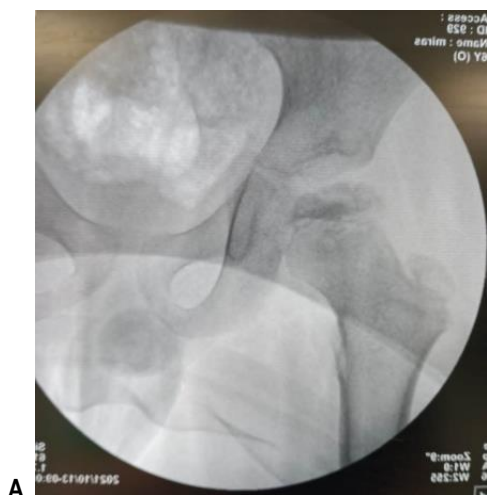
The half-rings of the Ilizarov apparatus were used as supporting elements. [16] The surgery was performed under general anesthesia. In the nadacetabular region of the pelvis and in the upper third of the thigh, 2 rods were held in different planes, the device is installed and fixed on the supporting elements of the external fixation apparatus (Figure 3).



Figure 1. Distraction system of the external fixation apparatus according to the Ilizarov type.

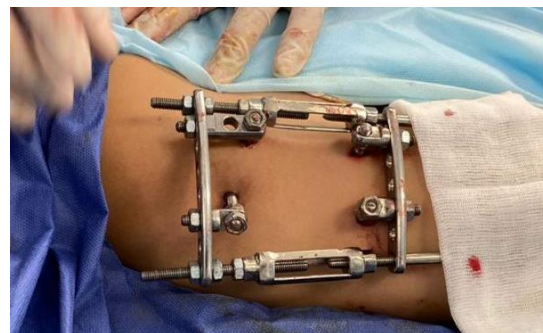

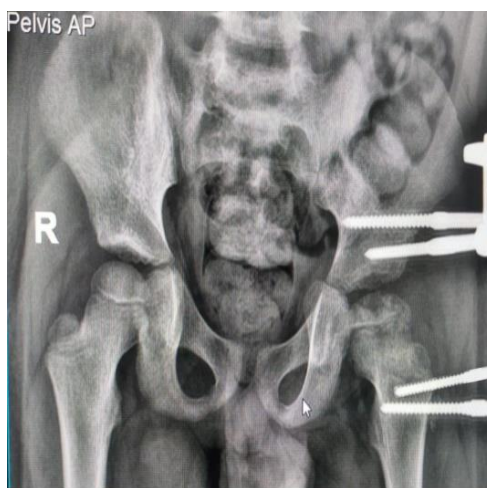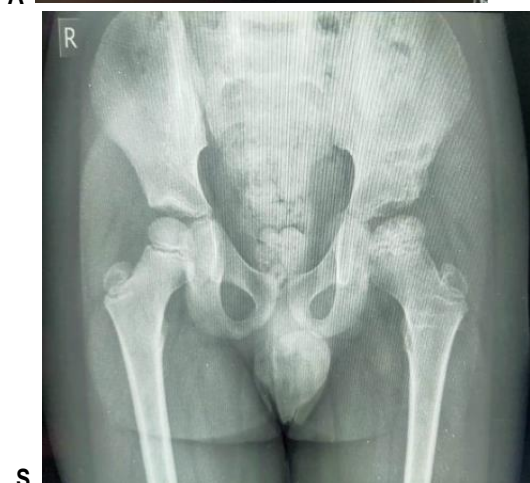Figure 2. Intraoperative photograph during the installation of the distraction system of the external fixation apparatus on the hip joint.



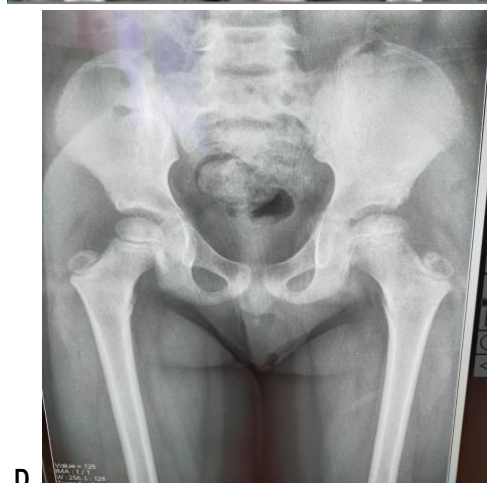A



B



C



D

Figure 3. A 7-year-old patient with Perthes disease. (a) The deformation, a decrease in the height of the head, with the presence of a pathological compression fracture of the epiphysis, is determined. Perthes disease in the stage of compression fracture and fragmentation (II-III stages). (b) on the 22nd day after the installation of the distraction system of the external fixation apparatus. (c) Radiograph after removal of the machine. After 3 months from the date of surgery. Perthes disease is under recovery. (e) after 10 months with an improvement in the epiphyseal index.

The femoral head is given an internal rotation of up to 20°. In the postoperative period, distraction begins during the operation by 1 mm, then by day 3, since the postoperative period is accompanied by pain syndrome for an average of three days, at a rate of 1 mm per day until the correction of the Shenton line is completed. After reaching the planned value, all elements of the rod are blocked until the device is removed. During the treatment, control radiography of the pelvis and hip joints was performed after 7, 14, 28 days (Figure 2).

The patient began to walk with a gradually increasing load from the first day after surgery with the help of crutches. The pain syndrome was not pronounced, complications were observed in the form of superficial inflammation of the soft tissues in the area of the rods.

Results

Radiologically, the severity of the disease and the indications for surgery were set according to the classifications of Salter-Thompson and Catterall. Ten patients were classified in Salter-Thompson group B; seven patients in group 4 and three patients in group 3 according to the Catterall classification, this means severe damage to the pineal gland, where the lateral segment of the epiphysis

of the femoral head is involved in the lesion, this is a prognostic factor for an unfavorable outcome of the disease.

For preoperative evaluation, anteroposterior and lateral radiographs of the pelvis in the Launstein pose were obtained.

The follow-up period ranged from 6 months to 4 years, with an average of 2 years. A total of 10 patients (9 boys and 1 girl) were enrolled in this study. The median age at symptom onset was 8.3 years-old (range 7–11 years-old) and the median age of having surgery was 9.1 years-old (range 7–11 years-old). Five cases are right-sided hip lesions, the remaining five are left-sided hip lesions. In the present study, there was not a single case of bilateral hip lesion. At the time of surgery, two patients had 2nd stage of the disease, eight patients had 3rd stage of the disease (20% in the second stage of the disease, 80% in the third stage). Distraction was performed over an average of 14 days (range 10-17 days). The median duration of AEF wearing was 30.6 days (range 28–39 days). None of these patients underwent any additional surgery. General characteristics of these patients are given in Table 1.

Table 1.

Characteristics of operated patients.

#	Sex	Age at debut	Age during surgical treatment	Duration of AEF wearing (days)	Duration of distraction (days)	Salter-Thompson Classification	Catterall Classification	Stulberg Classification	Complications	Affected joint
1	Male	9	10	36	10	B	4	I		Left
2	Male	7	8	34	14	B	4	III	Inflammation of the soft tissues	Right
3	Male	7	11	30	16	B	4	II		Right
4	Female	8	8	30	14	B	4	II		Left
5	Male	9	10	28	14	B	4	II		Right
6	Male	8	8	39	15	B	3	IV	Contracture	Left
7	Male	7	11	37	13	B	3	II		Left
8	Male	8	10	33	16	B	3	II		Right
9	Male	9	8	31	17	B	4	II		Left
10	Male	8	7	38	11	B	4	II		Right

The results of treatment were assessed by the volume of motion in the hip joint 3 months after surgery and comparing them with preoperative parameters, Table No. 2.

The degree of recovery of the epiphysis of the femoral head was assessed by comparing the preoperative and postoperative epiphyseal index.

Table 2.

The range of motion of the hip joint before and after surgery.

#	Inflection		Allocating		External rotation		Internal rotation	
	Before surgery	After surgery	Before surgery	After surgery	Before surgery	After surgery	Before surgery	After surgery
1	55°	90°	12°	35°	21°	33°	8°	24°
2	60°	95°	14°	39°	20°	34°	10°	25°
3	80°	110°	13°	37°	22°	35°	7°	21°
4	50°	89°	15°	38°	19°	32°	10°	30°
5	55°	95°	10°	30°	21°	34°	9°	25°
6	55°	90°	15°	37°	20°	35°	10°	26°
7	70°	95°	17°	39°	22°	35°	7°	22°
8	65°	95°	15°	35°	21°	33°	12°	30°
9	50°	120°	12°	40°	15°	40°	7°	30°
10	40°	60°	12°	20°	14°	25°	8°	15°

In a clinical examination performed 3 months after hip relief, the flexion range increased by an average of 40°, from 55° before surgery to 95° after surgery. Statistically significant differences were observed, $p=0.005$. The range of internal rotation increased by an average of 16° from 9° before surgery to 25° after surgery ($p=0.005$) and the range of external rotation increased by an average of 13° from 21° before surgery to 34° ($p=0.005$), and the angle of lead increased by an average of 23° from 14° before surgery to 37° postoperatively ($p=0.005$).

Table 3.

Radiological results.

#	Epiphyseal index (outcome)	Epiphyseal index (final)	Stulberg Classification
1	0,65	0,95	I
2	0,5	0,7	III
3	0,54	0,85	II
4	0,56	0,81	II
5	0,6	0,83	II
6	0,41	0,54	IV
7	0,55	0,85	II
8	0,58	0,86	II
9	0,67	0,8	II
10	0,68	0,86	II

The epiphyseal index showed a significant increase of an average of 0,24 from 0,18 to 0,31 postoperative surgery. There were statistically significant differences in the epiphyseal index before and after surgery, $p = 0.005$. According to the Stulberg classification [16], there was one class I hip, seven class II hips, one class III hip and one class IV hip, there were no class V results, diagram 1.

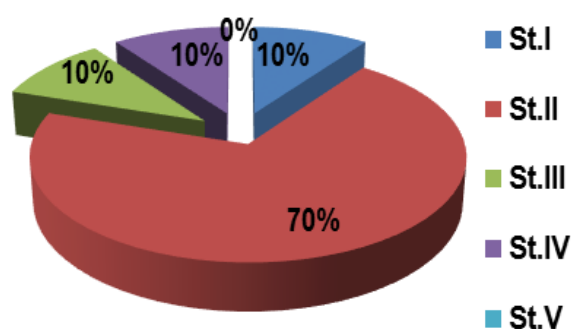


Diagram 1. Results according to the Stulberg classification.

The functional state of the hip joint was assessed using the Modified Harris Hip score questionnaire [17] three months, six months and nine months after surgery. At final follow-up, the average hip score for mHHS improved from 68 points before surgery to 85 points after surgery, $p < 0.005$.

In two patients, there was an infection around the rods, we believe that the cause is the mechanical removal of the hemorrhagic crust during the next dressings, which formed after surgery.

All patients were satisfied with the results, with the exception of one, the patient developed a deformity of the femoral head of the type of coxa plana.

A 7-year-old patient with Legg-Calve-Perthes disease of the left hip joint underwent hardware unloading using an

external fixation device, the device was used for 33 days. The range of motion increased by 30° in flexion, 10° in internal rotation, and 5° in abduction compared to preoperative measurements. On X-ray evaluation, the epiphyseal index increased from 16 before surgery to 26 after surgery. The Modified Harris Hip score improved from 69 points before surgery to 85 points after surgery. Thus, the hip was assigned to class II according to Stulberg, which indicates a satisfactory treatment result (Figure 2).

Discussion

Various treatments have been introduced to treat Legg-Calve-Perthes disease. However, the final criteria for the treatment of the disease have not been established, since the exact causes, pathogenesis and pathology of the disease are not fully understood. The prognosis and course of the disease are diverse and unpredictable, it can lead to degenerative arthritis in early childhood. The prognosis is worse in patients older than 6-8 years, primarily due to the fact that the remaining time for bone growth and repair is relatively short, and the depression of the femoral head progresses further due to physical reasons, such as decreased elasticity at the acetabulum [17-18].

During ischemia, the femoral head is subjected to pressure overload, even when the patient is at rest, due to the influence of the muscles. Unloading the hip joint allows you to expand the joint space, this creates an optimal environment for the restoration of the femoral head [19]. The circulation of synovial fluid and the nutrition of articular cartilage improves. In the apparatus, the articular surface and epiphysis are protected from the forces acting on the thigh, and the risk of deformation of the femoral head and the collapse of newly formed vessels are also reduced. In our case, rapid revascularization of the femoral epiphysis was observed in the interval of one to three months (Figure 2). This phenomenon was observed in studies by Volpon et al. [20]. According to Ilizarov's descriptions, unloading of the hip joint causes angiogenesis around the entire joint, active histogenesis occurs not only in the bone, but also in the soft tissue area [21]. According to the literature, 77.8% of patients have satisfactory treatment results for hip relief [22]. In our observation, the operated joint according to the classification of the outcome of the disease corresponds to class II according to Stulberg, this corresponds to the results of other authors. We came to the conclusion that when the hip joint was unloaded, the time of the stage of resorption and remodeling of the femoral head was shortened. The course of the rehabilitation period did not differ from the duration of treatment with the use of similar devices [23,24].

There are studies evaluating an apparatus with an articulating mechanism for unloading the hip joint, where the patient could perform passive movements in the joint, the duration of treatment using this technique ranged from 4 to 7 months [25]. We came to the conclusion that the presence of mobility in the hip joint during hardware treatment is not a significant fragment in the unloading of the hip joint. Mandatory therapeutic factors are the centered position of the head in the cavity, decompression of the hip joint, and improvement of local blood supply [26-29].

Thus, reconstructive surgery on the proximal femur is a priority. Reorientation of the femoral head in the cavity, restoration of the normal anatomy of the hip joint can

provide not only centering and full "coverage" of the femoral head, but also relieve pressure on the affected area. Subject to the availability of high-quality metal structures, practical experience of the surgeon, such operations are relatively less traumatic, do not require plaster immobilization, and provide the possibility of early, full-fledged rehabilitation. At the same time, they do not exclude the possibility of further reconstruction of the pelvic bones in dysplastic acetabulum formation [30-32].

Several studies emphasize that outcomes in LCPD are significantly influenced by patient age at onset, the extent of femoral head involvement, and the duration of the disease before intervention. In our study, the average age at onset (8.5–9 years) placed patients in a higher-risk group for residual deformities. Nevertheless, the use of distraction treatment demonstrated substantial improvement in function and structure.

The epiphyseal index was used as a radiological marker to evaluate morphological recovery of the femoral head. A significant increase in this index postoperatively in the distraction group supports its validity as an indicator of treatment success. Future protocols may benefit from incorporating dynamic monitoring of the epiphyseal index to guide treatment modifications during follow-up.

Although short-term functional and radiological outcomes are promising, LCPD is a condition with potential long-term sequelae, including early-onset osteoarthritis. Our findings emphasize the need for longitudinal cohort studies with follow-up beyond skeletal maturity to assess the durability of structural outcomes and correlate them with the eventual need for hip arthroplasty in adulthood.

Unloading the hip joint using an external fixation device is a relatively new treatment for Legg-Calvé-Perthes disease. Space is provided for the femoral head in the joint, minimizing physical pressure and keeping synovial fluid circulating.

Conclusions.

The advantages of our method are the correction of shortening, the simplicity of the technique, the minimum complication rate and the short period of hospitalization. The radiographic sphericity of the femoral head and the range of motion of the hip joint are improved, and the recovery time of the disease is reduced. Hardware unloading of the hip joint can make a good contribution to the treatment of Legg-Calvé-Perthes disease.

Author Contributions: All authors contributed equally to the writing of this manuscript.

Conflict of Interest: The authors declare no conflicts of interest. This material has not been submitted to other journals and is not under consideration elsewhere.

Funding: No funding was received for this study.

References:

1. Akhtyamov I., Abakarov A., Beletsky A., Bogosyan A., Sokolovsky O. Diseases of the hip joint in children. Kazan: Center for Operational Press, 2008. P. 456.
2. Armando O. R., Edgar H., Elba R. Legg-Calvé-Perthes disease overview. Orphanet J Rare Dis. 2022 Mar 15;17(1):125

3. Adam K, Manuel J.K., Andreas H.K. Proximal femoral varus osteotomy in Legg-Calvé-Perthes disease. Oper Orthop Traumatol. 2022 Oct;34(5):307-322.
4. Aguado M., Abril J.C., Bañuelos D.M. Garcia Alonso. Hip arthrodiastasis in Legg-Calvé-Perthes disease. Journal of Orthopaedics Surgery and Traumatology
5. Amer A., Khanfour A. Arthrodiastasis for late onset Perthes' disease using a simple frame and limited soft tissue release: early results. Acta Orthop Belg. 2011. 77(4). P.472–479
6. Bankes M., Valgus extension osteotomy for 'hinge abduction' in Perthes' disease. The Journal of Bone & Joint Surgery British Volume Vol 82-B, No.4. 01 May 2000. Pages 548 – 554
7. Barsukov D. Perthes disease. Terra Medica nova, 2009, 3: pp. 24–30.
8. Catterall A. Perthes' disease. J. Bone Joint Surg. [Br]. 1971. N53. P.37 –53
9. Ferguson A., Jr. Segmental vascular changes in the femoral head in children and adults. Clin Orthop Relat Res. 1985. 200. P.291-298.
10. Gafarov H. Treatment of children and adolescents with orthopedic diseases of the lower extremities. Kazan: Tatar book. publ., 1995, p.383.
11. George H Thompson. Salter osteotomy in Legg-Calvé-Perthes disease. 2011 Sep;31(2 Suppl): S192-198
12. Gregosiewicz A., Okonski M., Stolecka D. et al. Ischemia of the femoral head in Perthes' disease: is the cause intra- or extravascular? J Pediatr Orthop. 1989. 9. P.160-162.
13. Hall A., Barker D. The age distribution of Legg-Perthes disease. An analysis using Sartwell's incubation period model // Am J Epidemiol. 1984. 120. P. 531-536.
14. Herring J. Legg-Calvé-Perthes Disease. In Tachdjians Pediatric Orthopaedics J.A. Herring. Elsevier Health Sciences, 2001. P. 675-679.
15. Herring J. et al. Perthes' disease. J. Pediatr. Orthop. 1993. N13. P.41 –45.
16. Hosny G., El-Deeb K., Fadel M., Lakloul M. Arthrodiastasis of the hip. J. Pediatr. Orthop. 2011. Vol. 31, Suppl. 2. P. 229-234. doi: 10.1097/BPO.0b013e318223b45a.
17. Ilizarov G. The tension-stress effect on the genesis and growth of tissues. Transosseous osteosynthesis. Berlin: Springer-Verlag; 1992. P.137–255
18. Ibrahim Y., Mohamed Ahmed A., Kersh and Hesham Fahmy. Arthrodiastasis in the management of Perthes disease: a systematic review. Journal of Pediatric Orthopaedics B 2019, Vol XXX No XXX, P.5-11.
19. Ilizarov G. A method of bone fusion in fractures and an apparatus for the implementation of this method. Description of the invention. To the author's certificate. Published in the "Bulletin of Inventions" No. 6 for 1954
20. Krutikov N., Vinogradov A. Legg-Calvé-Perthes disease. Questions of modern pediatrics. 2015. 14. 5. P. 548-552.
21. Karagayur M., Makarevich P., Shevchenko E.K., Stambolsky D., Kalinina N., Parfyonova Ye. Modern approaches to peripheral nerve regeneration after injury: the prospects of gene and cell therapy. Genes and Cells. 2017. 12(1). P. 172-177.

22. Maxwell S., Lappin K., Kealey W., McDowell B., Cosgrove A. Arthrodiastasis in Perthes' disease. Preliminary results. J. Bone Joint Surg. Br. 2004. Vol. 86-B. No 2. P. 244-250.
23. Mehta J., Conybeare M., Hinves B. et al. Protein C levels in patients with Legg-Calvé-Perthes disease: is it a true deficiency? J Pediatr Orthop. 2006. 26. 200-203.
24. Perthes G. The classic: On juvenile arthritis deformans. 1910. Clin. Orthop. Relat. Res. 2012. 470 (9). 2349-2368.
25. Perry D., Skellorn P., Bruce C. The lognormal age of onset distribution in Perthes' disease: an analysis from a large well-defined cohort. J Bone Joint Surg Br. 2016. 98(5). pp. 110-114.
26. Perry D., Machin D., Pope D. et al. Racial and geographic factors in the incidence of Legg-Calvé-Perthes' disease: a systematic review. Am J Epidemiol. 2012. 175. P. 159-166.
27. Rajendra R. R., Christian M. Chiari osteotomy in Legg-Calvé-Perthes disease. J Pediatr Orthop B. 2005 Jan;14(1):1-9 Vol. 60. Issue 4. pages 243-250 (July - August 2016)
28. Reimers J. The stability of the hip in children. Acta Orthop. Scand. 1980. Suppl. No 184. P. 1-100.
29. Salter R. B., Thompson G. H. Legg-Calvé-Perthes Disease: the prognostic significance of the subchondral fracture and a two-group classification of the femoral head involvement. J. Bone Joint Surg. Am. 1984; 66: 479-489
30. Sokolovsky O., Dementsov A., Beletsky A., Brodko G. Modeling effect of triple pelvic osteotomy on the proximal femur in Perthes disease. 2009. C. 17, No 3. P. 112-120.
31. Stulberg S., Cooperman D., Wallensten R. The natural history of Legg-Calvé-Perthes disease. J. Bone Joint Surg Am. 1981. Sep. 63(7). 1095-1108.
32. Wen-Chao L, Rui-Jiang X., Lateral shelf acetabuloplasty for severe Legg-Calvé-Perthes disease in patients older than 8 years. 2016 Nov; 95(45): e5272

Information about the authors:

Tuktiyeva Nazym, Assistant of the Department of Traumatology and Pediatric Surgery, NCJSC «Semey Medical University», Semey, Republic of Kazakhstan; E-mail: tukti.nazym.anuarbek@gmail.com; phon: 8 (707) 694-90-06, <https://orcid.org/0000-0002-4024-6705>.

Dossanov Bolatbek, Ass. Professor of the Department of Pediatric Surgery, NCJSC «Astana Medical University», Astana, Republic of Kazakhstan; E-mail: dosanovb@mail.ru; phon: 8(7051034843); <https://orcid.org/0000-0001-9816-7404>.

Zhunussov Yersin, Professor of the International Science Center of Traumatology and Orthopedics. Almaty. Republic of Kazakhstan; E-mail: ersin-surgery@mail.ru; phon: 8(777)6238923; <https://orcid.org/0000-0002-1182-5257>.

Abdulvakhobov Gapsamet, The resident of the Department of Traumatology and Pediatric Surgery, NCJSC «Semey Medical University», Semey, Republic of Kazakhstan; phon: 8 (707) 6635690; <https://orcid.org/0009-0004-1097-8202>.

***Correspondence author:**

Tuktiyeva Nazym, Assistant of the Department of Traumatology and Pediatric Surgery, NCJSC «Semey Medical University», Semey, Republic of Kazakhstan;

Postal code: Republic of Kazakhstan, 071400, Semey city, Ibraeva Street 113.

E-mail: tukti.nazym.anuarbek@gmail.com

Phone: +7 7076949006