

Received: 13 May 2022 / Accepted: 16 August 2022 / Published online: 31 August 2022

DOI10.34689/SH.2022.24.4.001

UDK 616-079.1-24-002:578.834.1

## RADIOLOGICAL METHOD FOR THE DIAGNOSIS OF COVID-19 PNEUMONIA

**Madina R. Madiyeva**<sup>1</sup>, <https://orcid.org/0000-0001-6431-9713>

**Jamilya A. Mansurova**<sup>2</sup>, <https://orcid.org/0000-0003-2439-2056>

<sup>1</sup>NCJSC «Semey Medical University», Department of Radiology, Semey city, Republic of Kazakhstan.

<sup>2</sup>NCJSC «Semey Medical University», Department of Therapy, Semey city, Republic of Kazakhstan.

### Abstract

**Background.** Pneumonia is an acute infectious disease in which the respiratory sections of the lungs are affected with obligatory interalveolar exudation and infiltration of the parenchyma in response to the introduction of microorganisms. It is known that pneumonia is a clinical and radiological diagnosis. Chest CT scans are emerging as a useful tool in the diagnostic process of viral pneumonia cases associated with COVID-19. The CT manifestation of this viral pneumonia is non-specific but it has characteristic features based on which experienced radiologists can diagnose the disease. Findings are similar to other viral pneumonias but the localization of the signs is rather typical.

**Aim:** to present the main radiological findings of various types of pneumonia and COVID-19 pneumonia.

**Methods.** Generalized analysis of diagnosis of various types of pneumonia by the radiological method.

**Results.** The study shows the main radiological signs of pneumonia, including Covid-19. A description scheme of chest radiography and an algorithm for diagnosing the main types of pneumonia were also shown.

**Conclusion.** This article presents criteria for determining the severity of the condition of patients with coronavirus infection in accordance with radiological changes in the lung tissue.

**Keywords:** pneumonia, Chest CT scans, Chest X-ray, radiographic findings.

### Резюме

## РЕНТГЕНОЛОГИЧЕСКИЙ МЕТОД В ДИАГНОСТИКЕ COVID-19 ПНЕВМОНИИ

**Мадина Р. Мадиева**<sup>1</sup>, <https://orcid.org/0000-0001-6431-9713>

**Джамиля А. Мансурова**<sup>2</sup>, <https://orcid.org/0000-0003-2439-2056>

<sup>1</sup>НАО «Медицинский университет Семей», Кафедра радиологии, г. Семей, Республика Казахстан.

<sup>2</sup>НАО «Медицинский университет Семей», Кафедра терапии, г. Семей, Республика Казахстан.

**Актуальность.** Пневмония - острое инфекционное заболевание, при котором поражаются дыхательные отделы легких с обязательной межальвеолярной экссудацией и инфильтрацией паренхимы в ответ на внедрение микроорганизмов. Известно, что пневмония - это клинический и рентгенологический диагноз. Компьютерная томография грудной клетки становится полезным инструментом в процессе диагностики случаев вирусной пневмонии, связанных с COVID-19. КТ-проявление этой вирусной пневмонии неспецифично, но имеет характерные признаки, на основании которых опытные рентгенологи могут диагностировать заболевание. Результаты похожи на другие вирусные пневмонии, но локализация признаков довольно типична.

**Цель:** представить основные рентгенологические признаки различных типов пневмонии и пневмонии COVID-19.

**Методы.** Обобщенный анализ диагностики различных видов пневмонии рентгенологическим методом.

**Результаты.** В исследовании показаны основные рентгенологические признаки пневмонии, включая Covid-19. Также была показана схема описания рентгенографии грудной клетки и алгоритм диагностики основных видов пневмонии.

**Заключение.** В данной статье представлены критерии определения тяжести состояния пациентов с коронавирусной инфекцией в соответствии с рентгенологическими изменениями в легочной ткани.

**Ключевые слова:** пневмония, компьютерная томография грудной клетки, рентгенография грудной клетки, рентгенологические данные.

### Түйіндемe

## COVID-19 ПНЕВМОНИЯСЫН ДИАГНОСТИКАЛАУДАҒЫ РАДИОЛОГИЯЛЫҚ ӘДІС

**Мадина Р. Мадиева**<sup>1</sup>, <https://orcid.org/0000-0001-6431-9713>

**Джамиля А. Мансурова**<sup>2</sup>, <https://orcid.org/0000-0003-2439-2056>

<sup>1</sup>«Семей медицина университеті» КеАҚ, Радиология кафедрасы, Семей қ., Қазақстан Республикасы;

<sup>2</sup>«Семей медицина университеті» КеАҚ, Терапия кафедрасы, Семей қ., Қазақстан Республикасы.

**Өзектілігі.** Пневмония - жедел инфекциялық ауру, онда микроорганизмдердің енгізілуіне жауап ретінде өкпенің тынысалу бөлімдері міндетті түрде альвеолярлы экссудациямен және паренхиманың инфильтрациясымен әсеретеді. Пневмония клиникалық және рентгенологиялық диагноз екені белгілі. Кеуде қуысының компьютерлік томографиясы COVID-19-мен байланысты вирустық пневмония жағдайларын диагностикалау процесінде пайдалы құралға айналады. КТ - бұл вирустық пневмонияның көрінісі ерекше емес, бірақ тән белгілері бар, соның негізінде тәжірибелі рентгенологтар ауруды анықтай алады. Нәтижелер басқа вирустық пневмонияға ұқсас, бірақ белгілердің локализациясы өте тән.

**Мақсаты:** пневмониямен COVID-19 пневмониясының әртүрлі түрлерінің негізгі рентгенологиялық мәліметтерін ұсыну.

**Әдістері.** Рентгенологиялық әдіспен пневмонияның әртүрлі түрлерін диагностикалауды жалпыланған талдау.

**Нәтижелері.** Зерттеу пневмонияның негізгі рентгенологиялық белгілерін, соның ішінде Covid-19 көрсетеді. Сондай-ақ, кеуде қуысының рентгенографиясын сипаттау схемасы және пневмонияның негізгі түрлерін диагностикалау алгоритмі көрсетілді.

**Қорытынды.** Бұл мақалада өкпетіндегі рентгенологиялық өзгерістерге сәйкес коронавирустық инфекциясы бар пациенттердің жағдайының ауырлығын анықтау критерийлері берілген.

**Түйінді сөздер:** пневмония, кеуде қуысының компьютерлік томографиясы, кеуде қуысының рентгенографиясы, рентгенологиялық мәліметтер.

#### Bibliographic citation:

Madiyeva M.R., Mansurova J.A. Radiological method for the diagnosis of Covid-19 pneumonia // *Nauka i Zdravookhranenie* [Science & Healthcare]. 2022, (Vol.24) 4, pp. 6-11. doi 10.34689/SH.2022.24.4.001

Мадиева М.Р., Мансурова Д.А. Рентгенологический метод в диагностике Covid-19 пневмонии // *Наука и Здравоохранение*. 2022. 4(Т.24). С. 6-11. doi 10.34689/SH.2022.24.4.001

Мадиева М.Р., Мансурова Д.А. Covid-19 пневмониясын диагностикалаудағы радиологиялық әдіс // *Ғылым және Денсаулық сақтау*. 2022. 4 (Т.24). Б. 6-11. doi 10.34689/SH.2022.24.4.001

#### Introduction

According to official statistics, respiratory diseases are the most common conditions among children and adolescents in Kazakhstan [1]. The worldwide prevalence also remains at a fairly high level [4]. Diagnostic imaging plays a significant role in both the diagnosis and treatment of complications of pneumonia in adults and children.

Pneumonia is an acute infectious disease in which the respiratory sections of the lungs are affected with obligatory interalveolar exudation and infiltration of the parenchyma in response to the introduction of microorganisms.

According to the etiology, pneumonia is divided into bacterial, viral, and fungal. According to the Kazakh protocol for the diagnosis and treatment of pneumonia in adults (2013), the clinical classification is based on the development of the disease and the patient's immunological status [3]. The pneumonia protocol (2020) has been expanded with data on Covid-19 pneumonia [2].

It is known that pneumonia is a clinical and radiological diagnosis. X-Ray diagnostics is the most widely used approach, but its value is limited in mild forms of disease, as well as for prediction of clinical outcomes, and for differential diagnostics between viral and bacterial infections. Other methods such as CT and MRI are more informative, but their value in an uncomplicated disease is questionable. Limitation of the CT is related to the irradiation dose.

Radiological methods should confirm the diagnosis, fix the prevalence of the process, and identify complications and concomitant processes (bronchiectasis, tumors, previous lung diseases). Here we review the role of radiology in the diagnosis of pneumonia.

**Aim:** to present the main radiological findings of various types of pneumonia and COVID-19 pneumonia.

**Methods.** The analysis of the main radiological signs of pneumonia was carried out. Based on the analysis, an algorithm for diagnosing different types of pneumonia and a scheme for describing radiological images was formed. The Radiological Semiotics of pneumonia COVID-19 is presented.

*Inclusion criteria:* clinical and radiological signs of various types of pneumonia and COVID-19 pneumonia.

*Exclusion criteria:* radiological signs of other lung diseases.

*Key queries included:* pneumonia, chest X-ray, lung CT, COVID-19 pneumonia.

#### Results

Radiologists use systematic approach to the description of Chest Radiography. For the successful conclusion of any study in radiology, knowledge of the norm and a systematic approach are necessary. In order not to miss important information in the picture, a description should be carried out according to the same scheme (table 1, figure 1).

Table 1.

Scheme of Chest X-ray description.

Stages	Description
1. Identification	Checking the compliance of the patient information (name, date of birth and date of imaging), make sure that the image of the patient
2. Imagequality	«Soft”/“ Hard ”, correct patient installation, right / left side are indicated on the X-ray
3. Description	Explore the following structures: Trachea and anterior neck Pulmonary fields Sign of contour loss Mediastinum and heart Interlobar fissures Lung roots Aperture and the area below it Bones and soft tissue Artifacts Opacity and Lucency Syndromes
4. Conclusion	

The algorithm for the radiological conclusion of the main types of pneumonia is presented in the figure 1.

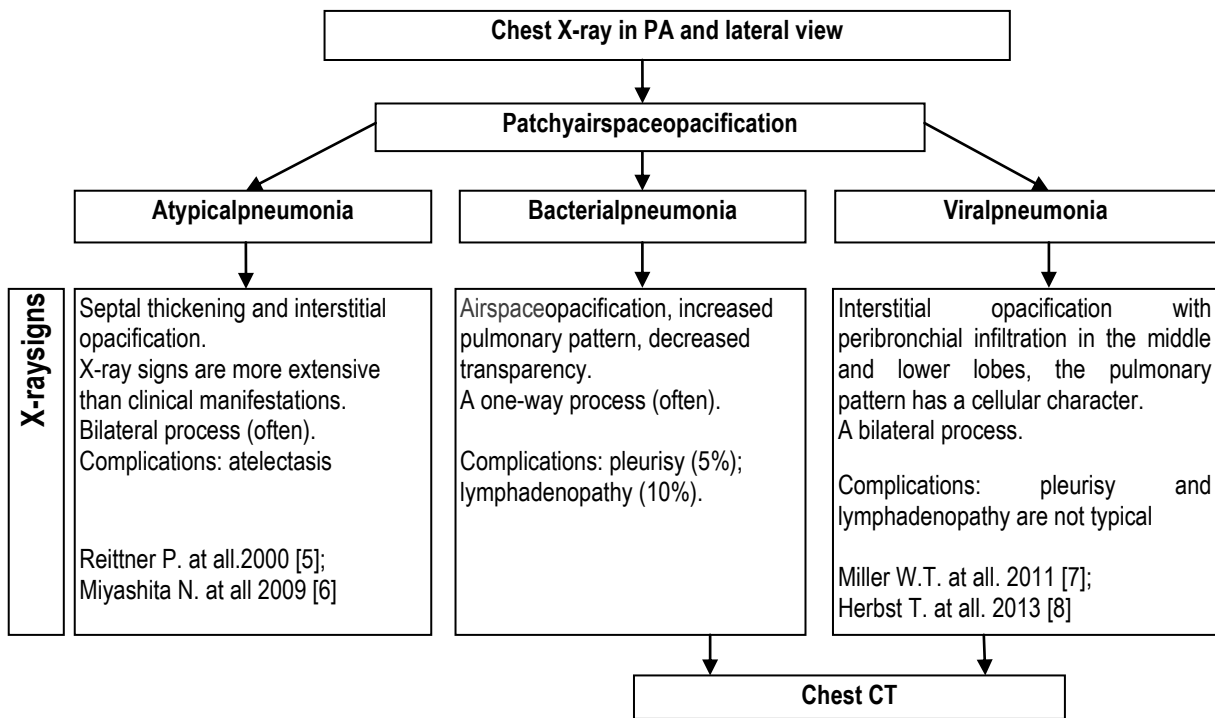


Figure 1. Algorithm of the main types of pneumonia.

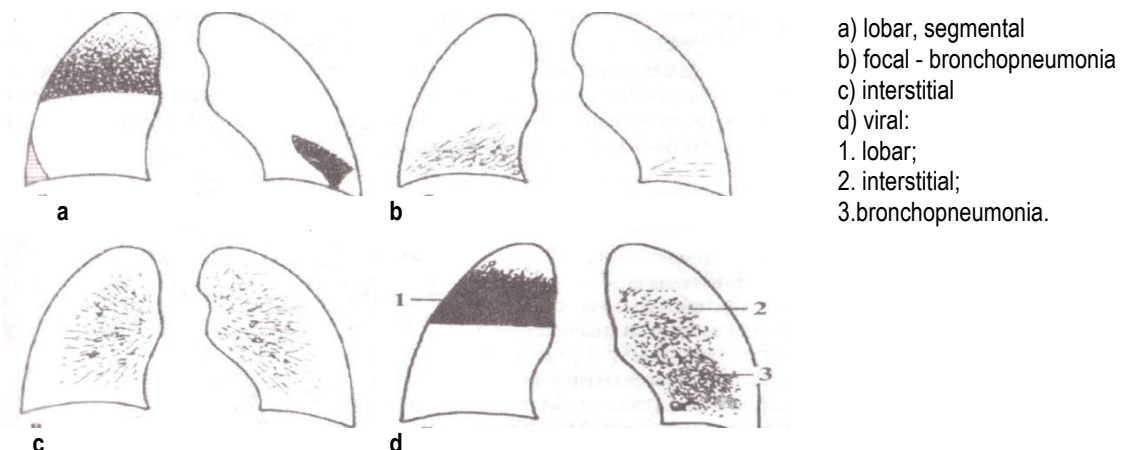


Figure 2. The main types of pneumonias.

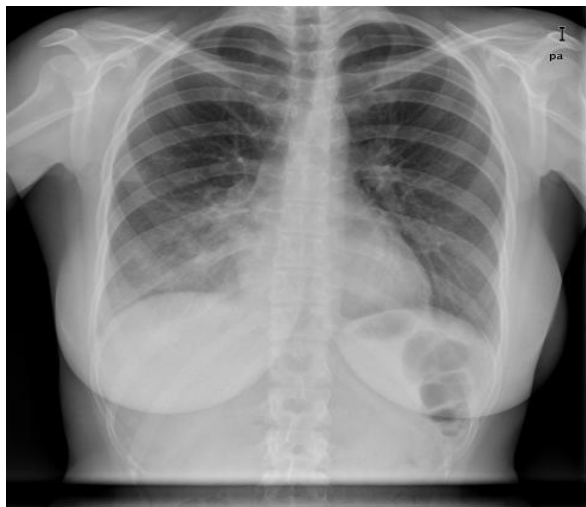
The most common way to examine the thorax is by radiography in the direct (PA) and lateral view. Special views are used for detailed study of localization of changes and observation of diaphragm excursion. Figure 2 shows the main types of pneumonias depending on the extent of the pathological process

**Radiological Semiotics of pneumonia COVID-19.** The diagnostics of COVID-19 includes epidemiological history, clinical picture, results of radiation and laboratory tests.

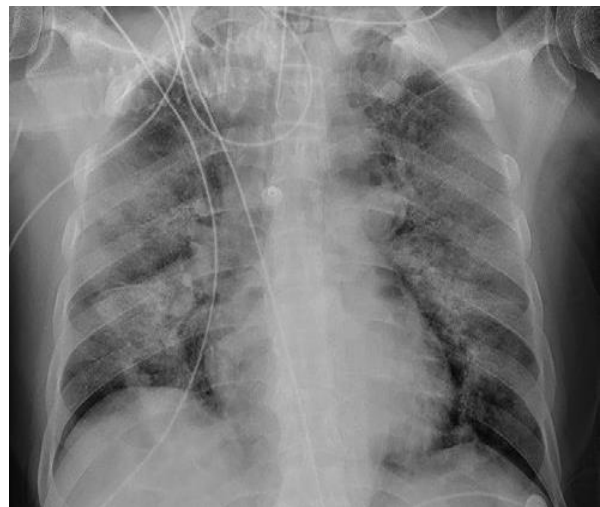**Chest x-ray.** Chest x-ray (CXR) is performed in the posterior-anterior and lateral view. When conducting CXR, the main radiological manifestations of viral pneumonia (including COVID-19) are: interstitial changes with peribronchial infiltration, numerous seals of "ground glass

opacity" with a rounded shape and various lengths (usually subpleural peripheral or basal location); infiltrative opacities. The bilateral lesion is more often. The volume of damages of lung segments correlates with the severity of the disease.

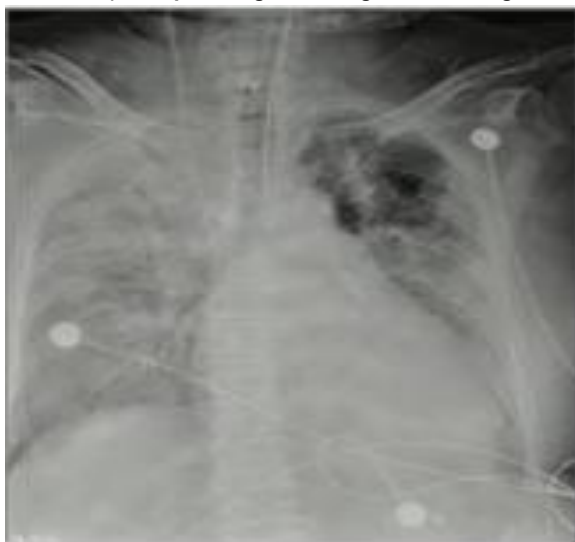Not typical for COVID-19 manifestations of CXR is: unilateral "ground glass opacity" of central and basal localization, pleural effusion, lymphadenopathy, segmental atelectasis, signs such as mild foci of the "ground glass opacity effect" and foci such as nodules may correspond to another disease. Figures 3 (a, b, c) show CXR of COVID-19 pneumonia in patients with various degrees of severity of pneumonia.



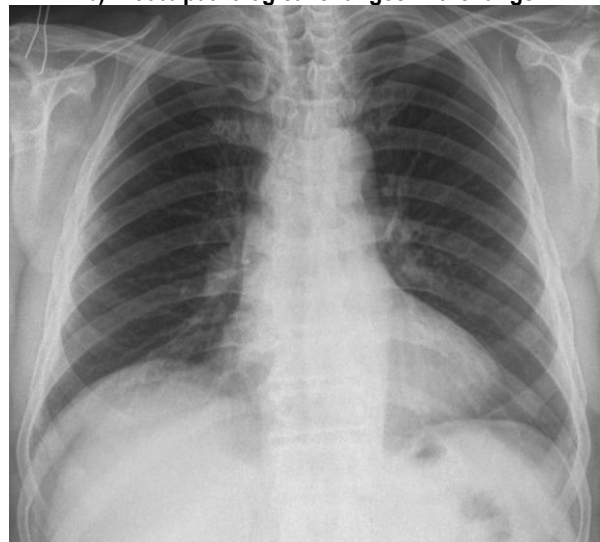
a) 25% pathological changes in the lungs



b) 50% pathological changes in the lungs



c) 75% pathological changes in the lungs.



d) No pathological changes in the lungs

Figure 3. Various degrees of severity of COVID-19 pneumonia (CXR).

**Computed tomography of the Chest (CT)** is performed using the standard Chest CT protocol. Typical radiological signs of viral pneumonia (including COVID-19) include:

- Numerous opacification "ground glass opacity" (GGO), mainly rounded, of various lengths;
- localization of peripheral, multilobar;

- the lesion is often bilateral (unilateral lesion is not often).

If there are clinical symptoms and one of the following radiological signs, says to *additional* signs:

- single or multiple foci of the type of GGO, thickening of the blood vessels of the lungs, a possible thickening of the interlobular septum ("crazy-paving" sign);

- airbronchography;
- the number of visible lung injuries exceeds two and is progressive;

- perilobular seals;

Radiological signs on Chest CT that are not typical for COVID-19:

- GGO of the central localization;
- single solid nodules;
- the presence of cavitation;
- pleural effusion;
- lymphadenopathy
- focal dissemination;
- symptom "tree in the kidneys";
- pneumosclerosis / pneumofibrosis;
- one-way localization.

When pneumonia COVID-19 has common symptoms with other viral, eosinophilic pneumonias, then during the

visualization process, it is difficult to identify. In this case, an epidemiological history, clinical symptoms and laboratory tests are needed, which can help in identification. Compared with acute respiratory viral infections and Bird Flu, in patients with pneumonia COVID-19, the disease will progress relatively slowly in the absence of other infections and complications. The disease mainly progresses within 7-10 days with an increase in the density of lesions compared to previous images and consolidated lesions with a symptom of air bronchogram. In critical cases, a further increase in compaction may be observed, with an even greater opaque decrease in the transparency of the lung tissue, which is sometimes described as a "white lung". Figure 4 presents Chest CT in patients with COVID-19 pneumonia.

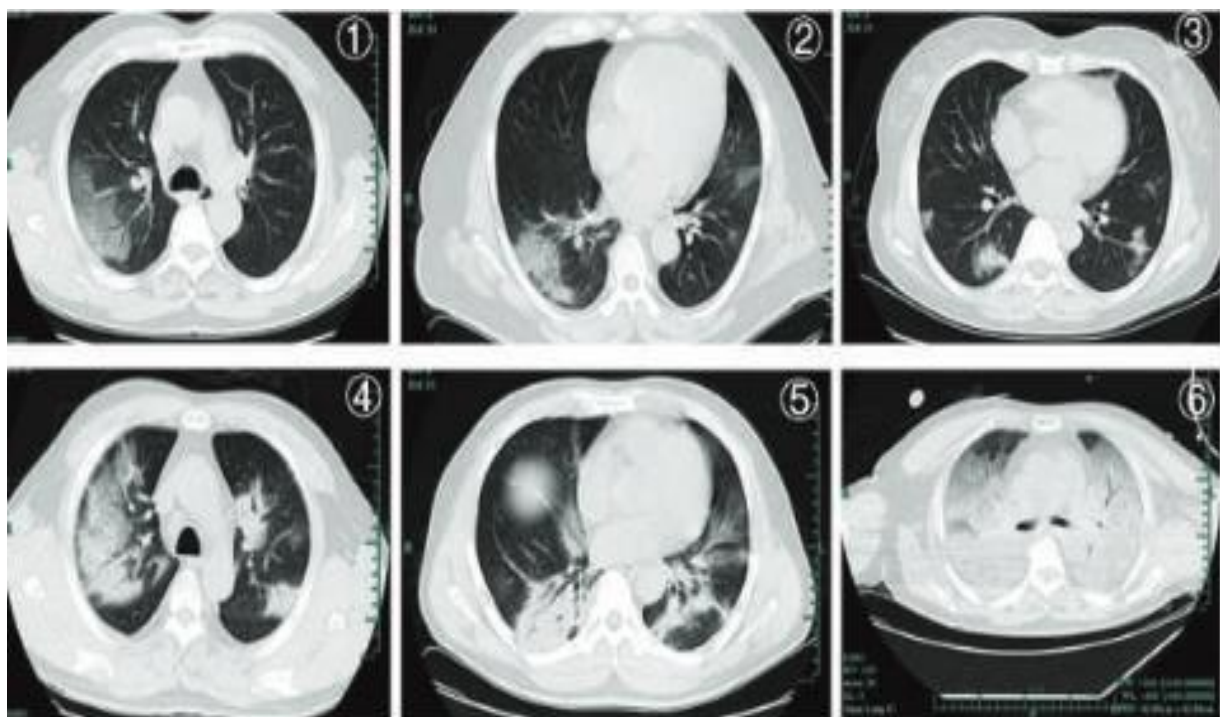


Figure 4. Typical Chest CT signs in patients with coronavirus infection [11].

- 4.1, 4.2 - Ground glass opacity;
- 4.3 - Nodules and focal exudation;
- 4.4, 4.5 – Consolidation;
- 4.6 - Diffuse consolidation "white lung".

Typical CT signs for each of the stages are shown in table 2. Assessment of severity is carried out by a cumulative assessment of the severity of general clinical data, X-ray picture, and laboratory tests.

Table 2.

**COVID-19 pneumonia course.**

Progress	Stages	CT signs
0-4 days	early	No signs, minimal changes in the type of ground glass opacity in the lower and subpleural regions
5-8 days	progression	Sealing long (the beginning of consolidation) Symptom of ground glass opacity, "quilt", reticular changes, in both lower lobes, the long axis of the lesion is mainly parallel to the pleura
8-14 days	late	Symptom of frosted glass diffuse arrangement, symptom of air bronchography, reticular changes, multiple consolidation ("white lung")
>14 days	Resolution	Partial or full resolution



The severity of CT correlates with the severity of the disease, so it seems rational to estimate the pathological involvement of the lungs. The essence of the method is to calculate the percentage involvement in the pathological process of each of the five lobes of the lung. The degree of involvement in the pathological process is expressed as a percentage: CT1-25%; CT2-50%; CT3-75%; CT4->75%.

Radiological signs of pneumonia may be absent in 18% of patients with a mild course of the disease and in 3% with a moderate/severe course.

#### Differential diagnosis

Viral pneumonia caused by COVID-19 does not have specific pathognomonic CT signs. Therefore, differential diagnosis (medical history, clinical, laboratory data) must be carried out with other types of pneumonia: other viral infections (influenza A and B viruses, parainfluenza viruses, adenovirus, respiratory syncytial virus, cytomegalovirus, SARS or MERS, etc.); non-infectious lung lesions: organized and eosinophilic pneumonia.

High sensitivity (67-100%) and relatively low specificity (25-80%) was reported [9,10] for the CT scans. In such cases, it is necessary to combine all the clinical symptoms, data on the patient's contact history, laboratory and Radiological studies.

#### Conclusion

This article presents criteria for determining the severity of the condition of patients with coronavirus infection in accordance with radiological changes in the lung tissue.

**Authors' Contributions:** All authors were equally involved in the research and writing of this article.

**Conflict of Interest:** The authors declare that they have no conflict of interest.

**Funding:** There is no financial support and sponsorship.

**Publication Information:** The results of this study have not been previously published in other journals and are not pending review by other publishers

#### Литература:

1. Кулманова Н.К., Доновбаева Б.К., Молдакулова Г.М. Здоровье подростков и молодежи как общественная ценность Казахстана. Аналитический отчет о положении семьи в Казахстане. Алматы, 2009. – 48 с.

2. Второй этап (продолженный) медицинской реабилитации, «Внебольничная пневмония, в том числе COVID-19 - пневмония» (взрослые), 2020 г. <http://surl.li/bzzob> (Дата обращения: 10.09.2020.)

3. Пневмония у взрослых, 2013 г. <http://surl.li/bzzoe> (Дата обращения: 10.07.2022.)

4. Walker C.L., Rudan I., Liu L., Nair H., Theodoratou E., Bhutta Z.A., et al. Global burden of childhood pneumonia and diarrhea // *Lancet*. 2013;381(9875):1405–16. [PMC free article] [PubMed] [Google Scholar]

5. Reittner P., Müller N.L., Heyneman L. et al. Mycoplasma pneumoniae pneumonia: radiographic and high-resolution CT features in 28 patients // *AJR Am J Roentgenol*. 2000. 174 (1): 37-41. doi:10.2214/ajr.174.1.1740037

6. Miyashita N., Sugiu T., Kawai Y. et al. Radiographic features of Mycoplasma pneumoniae pneumonia: differential diagnosis and performance timing // *BMC Med Imaging* 2009. 9 (1): 7. *BMC Med Imaging* (full text) - doi:10.1186/1471-2342-9-7

7. Miller W.T., Mickus T.J., Barbosa E. et al. CT of viral lower respiratory tract infections in adults: comparison among viral organisms and between viral and bacterial infections // *AJR Am J Roentgenol*. 2011. 197 (5): 1088-95. doi:10.2214/AJR.11.6501

8. Herbst T., Van Deerlin V.M., Miller W.T. The CT appearance of lower respiratory infection due to parainfluenza virus in adults // *AJR Am J Roentgenol*. 2013;201 (3): 550-4. doi:10.2214/AJR.12.9613

9. Kovacs A., Palasti P., Vereb D., Bozsik B. et al. The sensitivity and specificity of chest CT in the diagnosis of COVID-19 // *Eur Radiol*. 2021. 31(5): 2819–2824. doi:10.1007/s00330-020-07347-x

10. Wu J., Wu X., Zeng W. et al. Chest CT findings in patients with coronavirus disease 2019 and its relationship with clinical features // *Invest Radiol*. 2020. 55(5):257–261.

#### References: [1-3]

1. Kulmanova N.K., Donobaeva B.K., Moldakulova G.M. Zdorov'e podrostkov i molodezhi kak obshchestvennaya tsennost' Kazakhstana. Analiticheskii otchet o polozhenii sem'i v Kazakhstane [Health of adolescents and youth as a public value of Kazakhstan. Analytical report on the situation of the family in Kazakhstan]. Almaty, 2009. – 48 p. [in Russian]

2. Vtoroi etap (prodolzhennyi) meditsinskoi reabilitatsii, «Vnebol'nichnaya pnevmoniya, v tom chisle COVID-19 - pnevmoniya» (vzroslye), 2020 g. [The second stage (continued) of medical rehabilitation, "Community-acquired pneumonia, including COVID-19 - pneumonia" (adults)], 2020 <http://surl.li/bzzob> (Accessed: 10.09.2020)

3. Pnevmoniya u vzroslykh, 2013 g. [Pneumonia in adults], 2013 g. <http://surl.li/bzzoe> (Accessed: 10.07.2022)

#### Corresponding Author:

**Madiyeva Madina** – PhD, MD, ass. Professor, Head of the Department of Radiology, NCJSC «Semey Medical University», Semey city, Republic of Kazakhstan.

**Mailing Address:** 071412, Republic of Kazakhstan, Semey city, Karmenovast. 61-3.

**E-mail:** m.madiyeva@mail.ru; madina.madiyeva@nao-mus.kz

**Phone:** 87085244745