

Received: 01 December 2025 / Accepted: 05 April 2025 / Published online: 30 April 2025

DOI 10.34689/SH.2025.27.2.026

UDC 616-002.951.21



This work is licensed under a
Creative Commons Attribution 4.0
International License

A CLINICAL CASE OF ECHINOCOCCOSIS OF THE SPINE

Gulbarshyn D. Mukasheva¹, <https://orcid.org/0000-0003-3490-5628>

Saule B. Maukayeva¹, <https://orcid.org/0000-0002-2679-6399>

Nazym K. Kudaibergenova¹, <https://orcid.org/0000-0002-6165-7677>

Yerbol M. Smail¹, <https://orcid.org/0000-0003-3881-3747>

Gulnara I. Nuralinova¹, <https://orcid.org/0000-0002-0478-5154>

Dinara B. Kozubayeva¹, <https://orcid.org/0000-0003-4937-708X>

Dariya M. Shabdarbayeva¹, <https://orcid.org/0000-0001-9463-1935>

Zhanargyl K. Smailova¹, <https://orcid.org/0000-0002-4513-4614>

Duman Berikuly¹, <https://orcid.org/0000-0002-9738-7453>

Ainash S. Orazalina¹, <http://orcid.org/0000-0003-4594-0138>

Almira K. Akhmetova¹, <https://orcid.org/0000-0002-8938-3401>

Nailya M. Urazalina¹, <https://orcid.org/0000-0003-0200-1763>

Maiya V. Goremykina¹, <https://orcid.org/0000-0002-5433-7771>

Saya S. Karimova^{1*}, <http://orcid.org/0000-0002-1167-5375>

¹ NCJSC «Semey Medical University», Semey, Republic of Kazakhstan.

Abstract

Introduction. Cystic echinococcosis is a serious problem in various regions of the world. The prevalence of the disease ranges from 2 to 6 percent and higher. In Kazakhstan, echinococcosis occurs in the regions of the republic with developed livestock farming. The localization of the pathological process in echinococcosis can be different, which complicates the diagnosis and, as a consequence, the treatment of the disease.

Aim. To analyze a clinical case of echinococcosis with a rare localization of the pathological process in the spine.

Results of the study. The article presents a clinical case of echinococcosis with spinal lesions, which is an example of a rare lesion of the spine complicated by a paravertebral ductal abscess with the formation of a fistula in which chitinous membranes of echinococcus were found. Echinococcal lesions have no specific clinical and laboratory signs, which led to erroneous diagnosis of spinal tuberculosis with subsequent prescription of anti-tuberculosis drugs and surgical intervention, as a result of which echinococcus was detected during histological examination.

Conclusions. Doctors should be alert to echinococcosis, given the diverse localization of the parasite and the polymorphism of clinical manifestations. Successful treatment of the disease requires multidisciplinary work of doctors, reliable methods of laboratory and instrumental diagnostics, high-tech methods of surgical treatment.

Key words: echinococcosis, case, spine.

For citation: Mukasheva G.D., Maukayeva S.B., Kudaibergenova N.K., Smail Ye.M., Nuralinova G.I., Kozubayeva D.B., Shabdarbayeva D.M., Smailova Zh.K., Berikuly D., Orazalina A.S., Akhmetova A.K., Urazalina N.M., Goremykina M.V., Karimova S.S. A clinical case of echinococcosis of the spine // *Nauka i Zdravookhranenie* [Science & Healthcare]. 2025. Vol.27 (2), pp. 244-249. doi 10.34689/SH.2025.27.2.026

Резюме

КЛИНИЧЕСКИЙ СЛУЧАЙ ЭХИНОКОККОЗА ПОЗВОНОЧНИКА

Гүлбаршын Д. Мукашева¹, <https://orcid.org/0000-0003-3490-5628>

Сауле Б. Маукаева¹, <https://orcid.org/0000-0002-2679-6399>

Назым К. Кудайбергенова¹, <https://orcid.org/0000-0002-6165-7677>

Ербол М. Смаил¹, <https://orcid.org/0000-0003-3881-3747>

Гульнара И. Нуралинова¹, <https://orcid.org/0000-0002-0478-5154>

Динара Б. Козубаева¹, <https://orcid.org/0000-0003-4937-708X>

Дария М. Шабдарбаева¹, <https://orcid.org/0000-0001-9463-1935>

Жанаргуль К. Смаилова¹, <http://orcid.org/0000-0002-4513-4614>

Думан Берікұлы¹, <https://orcid.org/0000-0002-9738-7453>

Айнаш С. Оразалина¹, <http://orcid.org/0000-0003-4594-0138>

Альмира К. Ахметова¹, <https://orcid.org/0000-0002-8938-3401>

Найля М. Уразалина¹, <https://orcid.org/0000-0003-0200-1763>

Майя В. Горемыкина¹, <https://orcid.org/0000-0002-5433-7771>

Сая С. Каримова^{1*}, <http://orcid.org/0000-0002-1167-5375>

¹ НАО «Медицинский университет Семей», г. Семей, Республика Казахстан.

Введение. Кистозный эхинококкоз представляет собой серьезную проблему в различных регионах мира. Показатели распространенности заболевания колеблются от 2 до 6 процентов и выше. В Казахстане эхинококкоз встречается в областях республики с развитым животноводством. Локализация патологического процесса при эхинококкозе может быть различной, что затрудняет диагностику и как следствие лечение болезней.

Цель. Проанализировать клинический случай эхинококкоза с редкой локализацией патологического процесса в позвоночнике.

Результаты исследования. В статье представлен клинический случай эхинококкоза с поражением позвоночника, который является примером редкого поражения позвоночника, осложненного паравертебральным проточным абсцессом с образованием свища, в котором обнаружены хитиновые оболочки эхинококка. Эхинококковое поражение не имеет специфических клинико-лабораторных признаков, что привело к ошибочной диагностике туберкулеза позвоночника с последующим назначением противотуберкулезных препаратов и хирургического вмешательства, в результате которого при гистологическом исследовании был обнаружен эхинококк.

Выводы. Врачи должны быть настороже в отношении эхинококкоза, учитывая разнообразную локализацию паразита и полиморфизм клинических проявлений. Для успешного лечения заболевания необходимы мультидисциплинарная работа врачей, надежные методы лабораторной и инструментальной диагностики, высокотехнологичные методы хирургического лечения.

Ключевые слова: эхинококкоз, случай, позвоночник.

Для цитирования: Мукашева Г.Д., Маукаева С.Б., Кудайбергенова Н.К., Смаил Е.М., Нуралинова Г.И., Козубаева Д.Б., Шабдарбаева Д.М., Смаилова Ж.К., Берікұлы Д., Оразалина А.С., Ахметова А.К., Уразалина Н.М., Горемыкина М.В., Каримова С.С. Клинический случай эхинококкоза позвоночника // Наука и Здравоохранение. 2025. Т.27 (2), С. 244-249. doi: 10.34689/SH.2025.27.2.026

Түйіндеме

ОМЫРТҚА ЭХИНОКОККОЗЫНЫҢ КЛИНИКАЛЫҚ ЖАҒДАЙ

Гүлбаршын Д. Мукашева¹, <https://orcid.org/0000-0003-3490-5628>

Сауле Б. Маукаева¹, <https://orcid.org/0000-0002-2679-6399>

Назым К. Кудайбергенова¹, <https://orcid.org/0000-0002-6165-7677>

Ербол М. Смаил¹, <https://orcid.org/0000-0003-3881-3747>

Гульнара И. Нуралинова¹, <https://orcid.org/0000-0002-0478-5154>

Динара Б. Козубаева¹, <https://orcid.org/0000-0003-4937-708X>

Дария М. Шабдарбаева¹, <https://orcid.org/0000-0001-9463-1935>

Жанаргуль К. Смаилова¹, <http://orcid.org/0000-0002-4513-4614>

Думан Берікұлы¹, <https://orcid.org/0000-0002-9738-7453>

Айнаш С. Оразалина¹, <http://orcid.org/0000-0003-4594-0138>

Альмира К. Ахметова¹, <https://orcid.org/0000-0002-8938-3401>

Найля М. Уразалина², <https://orcid.org/0000-0003-0200-1763>

Майя В. Горемыкина¹, <https://orcid.org/0000-0002-5433-7771>

Сая С. Каримова^{1*}, <http://orcid.org/0000-0002-1167-5375>

¹ «Семей медицина университеті» КЕАҚ, Семей қ., Қазақстан Республикасы.

Кіріспе. Цистикалық эхинококкоз әлемнің әртүрлі аймақтарында күрделі мәселе болып табылады. Аурудың таралу деңгейі 2-ден 6 пайызға дейін немесе одан жоғары. Қазақстанда эхинококкоз республиканың мал шаруашылығы дамыған аймақтарында кездеседі. Эхинококкозға шалдыққан кездегі патологиялық процестің локализациясы әртүрлі болуы мүмкін, бұл диагнозды қиындатады және соның салдарынан ауруды емдеуді қиындатады.

Зерттеудің мақсаты. Омыртқадағы патологиялық процестің сирек локализациясы бар эхинококкоздың клиникалық жағдайын талдау.

Зерттеу нәтижелері. Мақалада эхинококкозға шалдыққан кезде жұлынның зақымдалғанын көрсеткен клиникалық жағдайы берілген, ол жұлынның паравертебральды түтік абсцессімен асқынған жұлынның сирек

зақымдалуының мысалы болып табылады, онда эхинококкоздың хитінді қабықшалары табылған фистула пайда болады. Эхинококты зақымданудың нақты клиникалық және зертханалық белгілері жоқ, бұл кейіннен туберкулезге қарсы препараттарды тағайындау және хирургиялық араласу арқылы жұлын туберкулезінің қате диагнозына әкелді, нәтижесінде гистологиялық зерттеу кезінде эхинококк анықталды.

Қорытынды. Дәрігерлер паразиттің әртүрлі локализациясын және клиникалық көріністердің полиморфизмін ескере отырып, эхинококкозға мұқият болуы керек. Ауруды сәтті емдеу үшін дәрігерлердің көп салалы жұмысы, зертханалық және аспаптық диагностиканың сенімді әдістері және хирургиялық емдеудің жоғары технологиялық әдістері қажет.

Түйінді сөздер: эхинококкоз, жағдай, омыртқа.

Дәйексөз үшін: Мукашева Г.Д., Маукаева С.Б., Кудайбергенова Н.К., Смаил Е.М., Нұралинова Г.И., Козубаева Д.Б., Шабдарбаева Д.М., Смаилова Ж.К., Берікұлы Д., Оразалина А.С., Ахметова А.К., Уразалина Н.М., Горемыкина М.В., Каримова С.С. Омыртқа эхинококкозының клиникалық жағдай // Ғылым және Денсаулық. 2025. Т.27 (2), Б. 244–249. doi: 10.34689/SH.2025.27.2.026

Introduction

Cystic echinococcosis is a serious problem in various regions of the world. Endemic zones are recorded in South America, the Middle East and the Eastern Mediterranean, in some countries of sub-Saharan Africa, in western China and the countries of the former Soviet Union [1-3]. The overall prevalence of echinococcal infection is underestimated because systematic population surveys are not conducted in all endemic areas. However, the number of detected cases is increasing, which may partly be due to the improvement of diagnostic technologies and surveillance programs. In endemic rural areas, prevalence rates range from 2 to 6 percent or higher [4]. In Peru, the prevalence of echinococcosis among humans, detected by ultrasound and/or chest X-ray, ranged from 3 to 9 percent [5-7]. The infection rate among dogs and sheep was 32 and 38 percent, respectively [5]. Between 2019 and 2021, 9511 cases of human cystic echinococcosis were reported in Peru, Argentina and Chile, accounting for 79, 12 and 9 percent of cases, respectively; 16 percent were associated with children under the age of 15 [8]. In the Chinese region, endemic to both *E. granulosus* and *E. multilocularis*, the prevalence rates of cystic echinococcus and alveolar echinococcus in rural areas were 6.8 and 6.2%, respectively [9]. The prevalence of cystic echinococcus ranged from 0 to 12 percent, and the prevalence of alveolar echinococcus ranged from 0 to 14 percent. In northern Xinjiang, China, 0.3-3 percent of the population were found to have cystic echinococcus cysts during ultrasound examination [10,11]. The highest prevalence (8.7%) was noted among Mongolian and Kazakh pastoralist communities [12]. These are some of the highest rates recorded worldwide. In a study conducted in Uruguay, it was noted that the overall prevalence was 5.6%; the prevalence increased from 1% among patients aged 4 to 6 years to more than 11% among patients over 60 years old [13]. In the United States, most cases occur among immigrants from endemic countries. Local transmission has been observed in California, Arizona, New Mexico, Utah and Alaska [4,14].

In Kazakhstan, echinococcosis occurs in all regions of the republic, but the most endemic region is the south of Kazakhstan, which is a large livestock center. The highest rates of infection of sheep were found in West Kazakhstan and Almaty regions - 16.7% and 12.52%. The existing system of accounting for patients with echinococcosis and statistical data do not fully reflect the real number of people

infected with echinococcosis, since only surgical cases are taken into account [15].

The localization of the pathological process in echinococcosis can be different, which makes it difficult to diagnose and, as a result, treat the disease.

Aim: to analyze a clinical case of echinococcosis with a rare localization of the pathological process in the spine.

Case.

Patient Zh., 42 years old, was admitted to the National Center for Tuberculosis Problems (NCPT) 14.08.2022 with complaints of pain in the thoracic spine, weakness in the lower extremities, general weakness, loss of appetite, weight loss.

From anamnesis: she fell ill in January 2020, when, after an examination, she was diagnosed with tuberculosis of the spine (pain in the lower thoracic spine, general weakness), for which she received category I treatment at the Regional Tuberculosis Dispensary (RPTD) in Semey. The treatment was completed in January 2021. In April 2022, pain in the thoracic and lumbar spine reappeared. She did not seek medical help. On 05.06.2022, after falling on her right side, the pain in his spine increased. She turned to the RPTD, where treatment for category II was started. However, against the background of treatment, the patient's condition worsened, weakness and restriction of movement in the lower extremities appeared. In this regard, the patient was sent to the National Tuberculosis Center for surgical treatment.

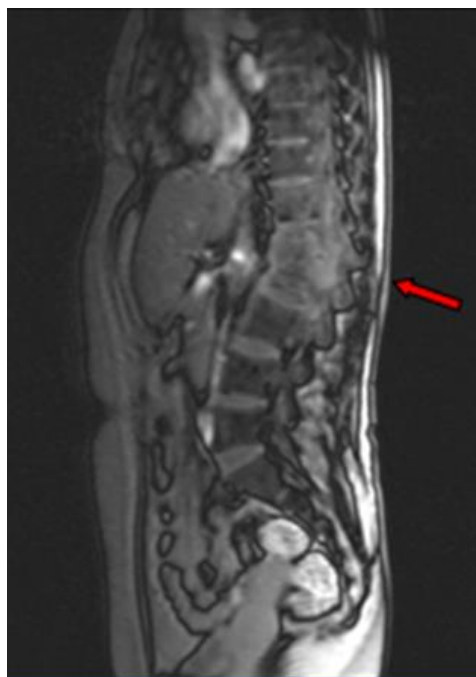
Objective: a condition of moderate severity. There were no abnormalities from the cardiovascular system, respiratory system and gastrointestinal tract.

Status localis: the muscles of the back are tense, there is a high standing of the spinous processes at the level of the bodies Th 12, L 1-2 vertebrae, with axial load at this level it is painful, movements in the lower extremities are limited, sensitivity in the lower extremities is preserved, the functions of the pelvic organs are not impaired.

The indicators of the general analysis of blood, urine and biochemical tests were within the normal range.

Chest X-ray from 26.06.2022: residual changes after pulmonary tuberculosis.

CT scan of the chest and abdominal organs from 16.08.2022: metastatic echinococcosis of both lungs? Echinococcal cysts of the retroperitoneal space on the right with displacement of the right kidney anteriorly and destruction of the vertebral bodies at the level of Th 11-12? (Figure 1, Figure 2)



Conglomerate at the level of Th₁₂, L₁₋₂, vertebrae with spinal canal stenosis with cyst formations.

Figure 1. CT scan of the chest and abdominal organs.

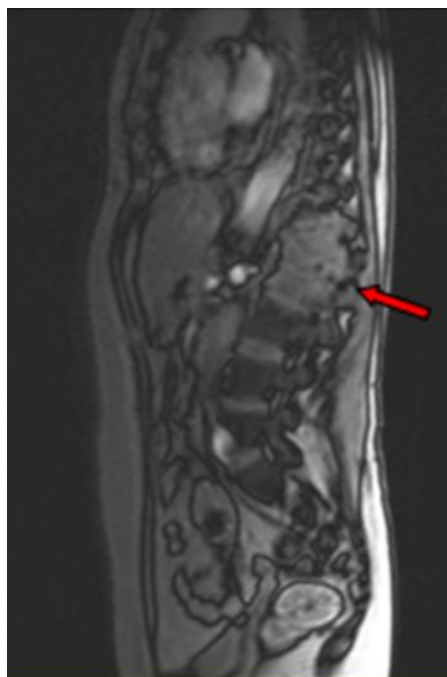
On 23.08.2022, the patient underwent surgery: lumbotomy on the right, abscessotomy, sequestration necrectomy Th 12, L 1-2. The results of the histological examination of the surgical material from 28.08.2022: there is no data for tuberculosis. Echinococcus of the spinal column with an inflammatory reaction.

On 29.08.2022, the diagnosis of tuberculosis was removed, echinococcosis of the spine was exposed. The patient was discharged from the NCPT on 21.09.2022 with the final diagnosis: Echinococcosis Th 12, L 1-2.

On September 25, 2022, the patient was admitted to the neurosurgical department of the Medical Center (MC) of the Semey Medical University (SMU). Upon admission: the condition is serious. A patient with low nutrition. An objective examination revealed lower paraparesis with a strength of up to 2.5 points, torpid tendon reflexes from the lower extremities. Of the local (local manifestations), the following were observed: tension of the back muscles, high standing of the spinous processes in the thoracolumbar region, gibus in the lower thoracic spine, painful palpation and axial load, abundant purulent discharge from the drainage tube in the right iliac region.

The patient was diagnosed. Common echinococcosis of the lungs, liver, Th 12, L 1-2 vertebrae, lower paraparesis. Pathological fracture Th 12, L 1-2. Psoaccess on both sides. Elements of spinal canal stenosis. Abscess of the retroperitoneal space and the right iliac region. Concomitant diagnosis: Chronic pyelonephritis. Exacerbation of Chronic renal failure (CRF). Iron deficiency anemia (IDA), grade 2, of mixed genesis.

On 09.10.2022, the patient underwent surgery: opening and drainage of the retroperitoneal and iliac abscess on the right. Ultrasound of the retroperitoneal space from 06.11.2022 – no pathology was detected in the retroperitoneal space. Upon discharge (13.11.2022), the patient's condition stabilized, persistent paraparesis



Destruction of vertebrae with destruction of discs.

Figure 2. CT scan of the chest and abdominal organs.

persisted with strength in the legs up to 3 points, rougher in the feet, elements of pelvic disorders.

On 14.01.2024, the patient was re-admitted to the neurosurgical department of the MC of SSMU with complaints of pain and burning in the thoracic spine, weakness in the legs, drooping feet - more on the left. The deterioration has occurred over the past two months. Upon admission, the condition is of moderate severity. From objective data, only: the lower paraparesis is deep distally up to 1.0 points. Locally: a postoperative scar on the right at the level of Th 11 with a length of up to 15 cm, in the left lumbar region there is a scarring with secondary tension of up to 3 cm in size.

On 15.01.2024, the patient underwent fistulography: there are fistulous passages in the paravertebral regions on the left at the level L 2-3, L 4-5. On 21.01.2024, the patient underwent surgery: lumbotomy on the left, revision and drainage of the abscess, fistulous passages were excised. Partial resection of the body of the L2 vertebra was performed. Drainage of a lumbotomic wound.

Pathohistological examination of the surgical material dated 29.01.2024: in the preparations, fat and muscle tissue with foci of necrosis surrounded by epithelioid cells, lymphocytes, giant multinucleated cells, fragments of chitinous membranes of echinococcus are visible in the foci of necrosis. Conclusion: echinococcosis in the area of the fistula.

Since August 2022, along with surgical treatment, the patient received 28-day cycles of anthelmintic treatment - albexol 675 mg in 2 doses, separated by a 14-day break in taking the drug.

Clinical diagnosis: Echinococcosis of the spinal canal at the level of Th 12, L 1-2 vertebrae, complicated by a paravertebral flow abscess with the formation of a fistula in the lumbar region on the left. Pathological fractures of the Th 12, L 1-2 vertebrae. Lower paraparesis. Concomitant diagnosis: Grade 1 IDA. Cardiosclerosis.

On 17.05.2024, the patient was discharged in a satisfactory condition. There is a wound in the lumbar region with a slight purulent discharge. Movement and strength in the lower extremities are reduced to 2 points.

"Written consent form" was obtained from the patient for the dissemination of his medical information.

Discussion. Echinococcal cysts can be found almost anywhere in the body, either as a result of primary infection or as a result of secondary spread. The liver is affected in about two thirds of patients, the lungs in about 25 percent, and other organs, including the brain, muscles, kidneys, bones, heart and pancreas, in a small proportion of patients. Damage to one organ occurs in 85-90% of patients with *E. granulosus* infection, and in more than 70% of cases there is only one cyst.

Bone cysts usually proceed asymptotically until a pathological fracture develops; the growth of the parasite in bone tissue is a very slow process; the spine, pelvis and long bones are most often affected [16,17]. The incidence of bone damage in Cystic Echinococcosis ranges from 0.5% to 4% of all cases of CE [18].

According to McManus DP and others (2003), primary extrahepatic is very rare (1%). Multiorgan disease was described in 13% of cases in one series, in which the parasites affected the lungs, spleen or brain in addition to the liver.

The rare localization of echinococcal cysts makes timely diagnosis difficult. In general, any extensive formation may clinically resemble an echinococcal cyst. The differential diagnosis of cystic echinococcosis includes various diseases, including tuberculosis [19]. Clinical features, laboratory and instrumental tests make it possible to differentiate similar conditions.

In the above clinical case, the patient was diagnosed with tuberculosis and received specific treatment for a long time, which could weaken the patient's immunity and lead to a prolonged course of echinococcosis [20].

Treatment of echinococcosis includes antiparasitic therapy in combination with either surgical resection of the cyst or percutaneous aspiration and instillation of scolicedal agents [21-23]. This patient underwent a combination of conservative and surgical therapy, which led to a positive result.

Conclusions

the presented clinical case of echinococcosis is an example of a rare spinal lesion complicated by a paravertebral flow abscess with the formation of a fistula, in which chitinous membranes of echinococcus were found. Echinococcal lesion has no specific clinical and laboratory signs, which led to an erroneous diagnosis of spinal tuberculosis, followed by the appointment of anti-tuberculosis drugs and surgery, as a result of which echinococcus was detected during histological examination. For the successful treatment of the disease, multidisciplinary work of doctors, reliable methods of laboratory and instrumental diagnostics, high-tech methods of surgical treatment are necessary.

Conflict of interest. No conflicts of interest have been declared.

Authors' Contributions. All authors participated equally in the writing of this article. This material has not been previously submitted for publication in other publications and is not under consideration by other publishers.

Funding. No funding was provided. There was no third-party funding or medical representation in the conduct of this work.

Literature:

1. Jenkins D.J., Romig T., Thompson R.C. Emergence/re-emergence of *Echinococcus* spp.--a global update. *Int J Parasitol* 2005; 35:1205. <https://doi.org/10.1016/j.ijpara.2005.07.014>
2. Romig T., Dinkel A., Mackenstedt U. The present situation of echinococcosis in Europe. *Parasitol Int* 2006; 55 Suppl:S187. <https://doi.org/10.1016/j.parint.2005.11.028>
3. Patemoster G., Boo G., Wang C., et al. Epidemic cystic and alveolar echinococcosis in Kyrgyzstan: an analysis of national surveillance data. *Lancet Glob Health* 2020; 8:e603. [https://doi.org/10.1016/s2214-109x\(20\)30038-3](https://doi.org/10.1016/s2214-109x(20)30038-3)
4. Moro P., Schantz P.M. Cystic echinococcosis in the Americas. *Parasitol Int* 2006; 55 Suppl:S181. <https://doi.org/10.1016/j.parint.2005.11.048>
5. Moro P.L., Bonifacio N., Gilman R.H., et al. Field diagnosis of *Echinococcus granulosus* infection among intermediate and definitive hosts in an endemic focus of human cystic echinococcosis. *Trans R Soc Trop Med Hyg* 1999; 93:611. [https://doi.org/10.1016/S0035-9203\(99\)90068-8](https://doi.org/10.1016/S0035-9203(99)90068-8)
6. Gavidia C.M. et al. Diagnosis of cystic echinococcosis, central Peruvian Highlands. *Emerg Infect Dis* 2008; 14:260. <https://doi.org/10.3201/eid1402.061101>
7. Tamarozzi F., Hou A., Morales M.L. et al. Prevalence and Risk Factors for Human Cystic Echinococcosis in the Cusco Region of the Peruvian Highlands Diagnosed Using Focused Abdominal Ultrasound. *Am J Trop Med Hyg* 2017; 96:1472. <https://doi.org/10.4269/ajtmh.16-0882>
8. OPS. Echinococcosis: Informe Epidemiológico en la Región de América del Sur-2019-2021. Centro Panamericano de Fiebre Aftosa y Salud Pública Veterinaria (PANAFTOSA/SPV): n. 5. 2022. Available online: <https://iris.paho.org/handle/10665.2/56620>.
9. Tiaoying L., et al. Echinococcosis in Tibetan populations, western Sichuan Province, China. *Emerg Infect Dis* 2005; 11:1866. <https://doi.org/10.3201/eid1112.050079>
10. Chai J.J., Jiao W. et al. An epidemiological survey of current status of cystic echinococcosis in northern Xinjiang. *J Trop Dis Parasitol* 2004; 2:139.
11. Nurguli A., Azhener Z., Buerliesi S. The current epidemiological status of hydatid disease in Tuoli County, Xinjiang. *Chin Foreign Med Res* 2010; 8:109.
12. Wang G.Z. et al. Epidemiological study on human echinococcosis in Hobukesar Mongolian autonomous county of Xinjiang. *Chin J Endemiol* 2009; 28:214. <https://doi.org/10.3760/cma.j.issn.0253-9624.2016.07.007>
13. Cohen H., Paolillo E. et al. Human cystic echinococcosis in a Uruguayan community: a sonographic, serologic, and epidemiologic study. *Am J Trop Med Hyg* 1998; 59:620. <https://doi.org/10.4269/ajtmh.1998.59.620>
14. Cerda J.R., Buttke D.E., Ballweber L.R. *Echinococcus* spp. Tapeworms in North America. *Emerg Infect Dis* 2018; 24:230. <https://doi.org/10.3201/eid2402.161126>
15. Jalyshева S.V., Abdybekova A.M. O rasprostraneni ekhinokokkoza v Respublike Kazakhstan [On the spread of echinococcosis in the Republic of Kazakhstan] 2022.Tom 91 №2. *Vestnik KazNU. Seriya biologicheskaya* [Vestnik Kaznu. Biological series]. <https://doi.org/10.26577/eb.2022.v91.i2.010> [in Russian].
16. Zlitni M, Ezzaouia K, Lebib H, et al. Hydatid cyst of bone: diagnosis and treatment. *World J Surg* 2001; 25:75. <https://doi.org/10.1007/s002680020010>

17. Cattaneo L., Manciuoli T. et al. Cystic Echinococcosis of the Bone: A European Multicenter Study. *Am J Trop Med Hyg* 2019; 100:617. <https://doi.org/10.4269/ajtmh.18-0758>

18. Monge-Maillo B, Lopez-Velez R. Cystic echinococcosis of the bone. *Curr Opin Infect Dis* 2023; 36:341. <https://doi.org/10.1097/qco.0000000000000951>

19. Rinaldi F., Brunetti E., Neumayr A., et al. Cystic echinococcosis of the liver: A primer for hepatologists. *World J Hepatol* 2014; 6:293. <https://doi.org/10.4254/wjh.v6.i5.293>

20. Kern P., Bardonnnet K., Renner E., et al. European echinococcosis registry: human alveolar echinococcosis, Europe, 1982-2000. *Emerg Infect Dis* 2003; 9:343. <https://doi.org/10.3201/eid0903.020341>

21. Brunetti E., Kern P., Vuitton D.A. Writing Panel for the WHO-IWGE. Expert consensus for the diagnosis and treatment of cystic and alveolar echinococcosis in humans. *Acta Trop* 2010; 114:1. <https://doi.org/10.1016/j.actatropica.2009.11.001>

22. Stojković M., Weber T.F., Junghanss T. Clinical management of cystic echinococcosis: state of the art and perspectives. *Curr Opin Infect Dis* 2018; 31:383. <https://doi.org/10.1097/qco.0000000000000485>

23. Rinaldi F., Brunetti E., Neumayr A., et al. Cystic echinococcosis of the liver: A primer for hepatologists. *World J Hepatol* 2014; 6:293. <https://doi.org/10.4254/wjh.v6.i5.293>

Information about the authors:

Mukasheva Gulbarshyn Darynkyzy - Senior Teacher of the Department of Epidemiology and Biostatistics, NJSC "Semey Medical University", Semey, Kazakhstan; E-mail: gulbarshyn_1_12@mail.ru; phone +7 775 220 07 45;

Maukayeva Saule Boranbayevna - Candidate of Medical Sciences, Associate Professor of the Department of Infectious Diseases, Dermatovenereology and Immunology, NJSC «Semey Medical University» phone: 8 705 529 66 75, e-mail: solly66@mail.ru, <https://orcid.org/0000-0002-2679-6399>, Semey, Kazakhstan;

Kudaibergenova Nazym Konyrovna - Candidate of Medical Sciences, Associate Professor of the Department of Infectious Diseases, Dermatovenereology and Immunology, NJSC «Semey Medical University», phone: 8 705 188 08 36, e-mail: nazym.kudaibergenova@smu.edu.kz, <https://orcid.org/0000-0002-2679-6399>, Semey, Kazakhstan;

Smail Yerbol Muslimovich - Associate professor, department of infectious diseases, dermatovenereology and immunology, NJSC «Semey Medical University», phone: 8 705 528 84 09. E-mail: erbol.smail@smu.edu.kz, <https://orcid.org/0000-0003-3881-3747>, Semey, Kazakhstan;

Nuralinova Gulnar Inzhikanovna - Candidate of Medical Sciences, Associate Professor of the Department of Infectious Diseases, Dermatovenereology and Immunology, NJSC «Semey Medical University», phone: 8 705 409 41 09, e-mail: gulnarnuralinova5@gmail.com, <https://orcid.org/0000-0002-0478-5154>, Semey, Kazakhstan;

Kozubayeva Dinara Begimhanovna - Assistant, department of infectious diseases, dermatovenereology and immunology, NJSC «Semey Medical University», phone: 8 775 342 16 44, Kazakhstan. E-mail: dinara_begimhanovna@mail.ru, ORCID 0000-0003-4937-708X, Semey, Kazakhstan;

Shabdarbayeva Dariya Muratovna – Doctor of Medical Sciences, Professor, Vice Rector for Science and Strategic Development", NJSC «Semey Medical University», phone 8 707 365 82 71, e-mail: dariya_kz@bk.ru, <https://orcid.org/0000-0001-9463-1935>, Semey, Kazakhstan;

Smailova Zhanargyl Kaiyrgaliyevna - Candidate of Medical Sciences, Associate Professor, Vice Rector for Academic and Educational Work, NJSC «Semey Medical University», phone 8 777 114 64 94, e-mail: zhanargul.smailova@smu.edu.kz; <https://orcid.org/0000-0002-4513-4614>

Berikuly Duman - PhD of Public Health, Vice-Rector for Postgraduate Education and Organizational Issues, NJSC «Semey Medical University», phone: 8 705 506 56 09; e-mail: duman.berikuly@smu.edu.kz; <https://orcid.org/0000-0002-9738-7453>;

Orazalina Ainash Saparovna – Candidate of Biological Sciences, Associate Professor, Head of the Department of Molecular Biology and Medical Genetics named after Academician of the National Academy of Sciences of the Republic of Kazakhstan T.K. Raisov, NJSC «Semey Medical University», phone; +7-777-235-47-72; e-mail: ainash.orazalina@smu.edu.kz; <https://orcid.org/0000-0003-4594-0138>; Semey, Kazakhstan;

Akhmetova Almira Kalikapasovna - Acting Professor of the Dermatovenereology Course, Associate Professor, Candidate of Medical Sciences, department of infectious diseases, dermatovenereology and immunology, NJSC «Semey Medical University», phone: 8 701 388 1337, Kazakhstan. E-mail: almira.akhmetova@smu.edu.kz, ORCID 0000-0002-8938-3401, Semey, Kazakhstan;

Urazalina Nailya Murathanovna - Candidate of Medical Sciences, Associate Professor of the Department of physiological disciplines named after honored scientist of the republic of Kazakhstan, professor T.A. Nazarova, NJSC «Semey Medical University», phone: 8 777 907 55 89, e-mail: hakim_15@mail.ru, <https://orcid.org/0000-0003-0200-1763>, Semey, Kazakhstan;

Goremykina Maya Valentinovna - Candidate of Medical Sciences, Associate Professor, Department of Internal Medicine and Rheumatology, NJSC «Semey Medical University», 103 Abay street, Semey, 071400, Kazakhstan; Email: maya.goremykina@smu.edu.kz; phone number: +7 (777) 390 8234; <https://orcid.org/0000-0002-5433-7771>

Karimova Saya Sayankyzy- Assistant, department of infectious diseases, dermatovenereology and immunology, NJSC «Semey Medical University», phone: 8 701 106 96 13, Kazakhstan. E-mail: saya.karimova.94@mail.ru, ORCID 0000-0002-1167-5375, Semey, Kazakhstan;

*Correspondence author:

Karimova Saya Sayankyzy - Assistant, department of infectious diseases, dermatovenereology and immunology, NJSC «Semey Medical University», Semey, Kazakhstan;

Post address: 103 Abay Street, Semey city, 071400, Republic of Kazakhstan;

E-mail: saya.karimova.94@mail.ru

Phone: 8 701 106 96 13