

Получена: 24 Августа 2024 / Принята: 27 Декабря 2024 / Опубликовано online: 30 Декабря 2024

DOI 10.34689/SH.2024.26.6.024

UDC 616.25-089.48 (053.2)



USE OF A NEW DEVICE FOR DRAINAGE OF THE PLEURAL CAVITY IN CHILDREN

Assylzhan M. Messova¹, <https://orcid.org/0000-0001-5373-0523>

Makhmutbay Sanbayev¹, <https://orcid.org/0000-0001-8681-6972>

Raikhan B. Temirkhanova²,

Oxana A. Yurkovskaya², <https://orcid.org/0000-0002-6251-5574>

Yulia G. Popovich²,

Gulyash A. Tanysheva², <https://orcid.org/0000-0001-9531-5950>

¹ Astana medical University, Astana, Republic of Kazakhstan;

² Semey medical University, Semey, Republic of Kazakhstan.

Abstract

We have received a patent for a utility model of the Republic of Kazakhstan No. 97674 dated 05/03/2016 with the name trocar for thoracentesis in children, which is effectively used for drainage of the pleural cavity in acute bacterial destructive pneumonia (ABDP) in children. For thoracentesis, a trocar with a handle having a cannula and a stylet with a pointed cone-shaped perforator placed in it is used. The cannula and stylet, respectively, have a 90-degree bend. When using a device for thoracentesis, due to the arcuate bend of the cannula, it is easy to correctly install the drainage tube along the chest in the apical direction, which ensures effective drainage and sanitation of the pleural cavity in case of pyopneumothorax in children. A sharp cone-shaped stylet perforator, reducing trauma to soft tissues, can reduce the time of surgery, which improves treatment outcomes and length of stay in the hospital. The device was used in 27 children with the pulmonary pleural form (PPF) of APDP; complications were observed in one patient (wound suppuration in the drainage area). The manipulation is easily learned by general practitioners. At the same time, the average time to perform the manipulation was 10-12 minutes.

Key words: patent, trocar, acute bacterial destructive pneumonia, drainage of the pleural cavity, children.

Резюме

ИСПОЛЬЗОВАНИЕ НОВОГО УСТРОЙСТВА ДЛЯ ДРЕНИРОВАНИЯ ПЛЕВРАЛЬНОЙ ПОЛОСТИ У ДЕТЕЙ

Асылжан М. Месова¹, <https://orcid.org/0000-0001-5373-0523>

Махмутбай Санбаев¹, <https://orcid.org/0000-0001-8681-6972>

Райхан Б. Темирханова²,

Оксана А. Юрковская², <https://orcid.org/0000-0002-6251-5574>

Юлия Г. Попович²,

Гульаш А. Танышева², <https://orcid.org/0000-0001-9531-5950>

¹ НАО «Медицинский университет Астана», г. Астана, Республика Казахстан;

² НАО «Медицинский университет Семей», г. Семей, Республика Казахстан.

Нами получен патент на полезную модель Республики Казахстан №97674 от 03.05.2016г. на троакар для торакоцентеза у детей, который с эффективностью используется для дренирования плевральной полости при острой бактериально-деструктивной пневмонии (ОБДП) у детей. Для торакоцентеза применяется троакар с ручкой, имеющей канюлю и размещенной в нем стилет с заостренным конусовидным перфоратором. Канюля и стилет соответственно имеют изгиб с углом 90 градусов. При применении устройства для торакоцентеза, из-за дугообразного изгиба канюли легко удается правильно установить дренажную трубку вдоль грудной клетки в апикальном направлении, что обеспечивает эффективное дренирование и санацию плевральной полости при пиопневмотораксе у детей. Острый конусовидный перфоратор стилета уменьшает травматизацию мягких тканей позволяет сократить время проведения операции, что улучшает исходы лечения и сроки пребывания в стационаре. Устройство использовано у 27 детей с легочно-плевральной формой (ЛПФ) ОБДП, осложнения наблюдались у одного больного (нагноение раны в области дренажа). Проведение манипуляции легко усваивается врачами общей практики. При этом, среднее время выполнения манипуляции составило 10-12 минут.

Ключевые слова: патент, троакар, ОБДП, дренирование плевральной полости, дети.

Түйіндеме

**БАЛАЛАРДА ӨКПЕ ҚУЫСЫН ДРЕНАЖДАУ ҮШІН
ЖАҢА ҚҰРЫЛҒЫНЫ ҚОЛДАНУ****Асылжан М. Месова¹**, <https://orcid.org/0000-0001-5373-0523>**Махмутбай Санбаев¹**, <https://orcid.org/0000-0001-8681-6972>**Райхан Б. Темирханова²**,**Оксана А. Юрковская²**, <https://orcid.org/0000-0002-6251-5574>**Юлия Г. Попович²**,**Гуляш А. Танышева²**, <https://orcid.org/0000-0001-9531-5950>¹ «Астана медицина университеті» КеАҚ, Астана қ, Қазақстан Республикасы;² «Семей медицина университеті» КеАҚ, Семей қ, Қазақстан Республикасы.

Біз Қазақстан Республикасының пайдалы моделіне 03.05.2016 жылғы № 97674 патент алдық, ол балаларда өкпенің жедел бактериалық деструкциясында дамыған пиопневмоторакста (ӨЖБД) өкпе қуысын дренаждау кезінде тиімділігін көрсетті. Торакоцентез жасау үшін конюласы мен стилеті 90 градустан доға тәрізді иінделген троакар-тескіш қолданылды. Троакардың стилетінің үші конус тәрізді үшкір және өткір болып келеді. Доға тәрізді иілген канюля арқылы дренаждау арналған түтікті жоғары қарай еш қиындықсыз кеуде қуысыныңдағы қабырға бойымен апикалды бағытта қажетті ұзындықта орналастырылады. Ал стилеттің конус тәрізді үшкір және өткір ұшы жұмсақ тіндер мен қан тамырларын жарақаттаудың алдын ала отырып, операция жасау уақытын қысқартуға мүмкіндік туғызады. Құрылғы 27 науқасқа қолданылып оң нәтежеге қол жеткіздік, тек 1 науқаста түтікше төңірегінде жарада іріңдеу байқалды. Операцияның орташа уақыты 10-12 минут. Операцияны жалпы тәжірибелік дәрігерлер тез игеріп алады.

Түйінді сөздер: патент, троакар, өкпенің жедел бактериалық деструкциясы, кеуде қуысын дренаждау, бала.

For citation/ Для цитирования/ Дәйексөз үшін:

Messova A.M., Sanbaev M., Temirkhanova R.B., Yurkovskaya O.A., Tanysheva G.A., Popovich Yu.G. Use of a new device for drainage of the pleural cavity in children // *Nauka i Zdravookhraneniye* [Science & Healthcare]. 2024. Vol.26 (6), pp. 219-224. doi 10.34689/SH.2024.26.6.024

Месова А.М., Санбаев М., Темирханова Р.Б., Юрковская О.А., Танышева Г.А., Попович Ю.Г. Использование нового устройства для дренирования плевральной полости у детей // *Ғылым және Денсаулық сақтау*. 2024. Т.26 (6). С. 219-224. doi 10.34689/SH.2024.26.6.024

Месова А.М., Санбаев М., Темирханова Р.Б., Юрковская О.А., Танышева Г.А., Попович Ю.Г. Балаларда өкпе қуысын дренаждау үшін жаңа құрылғыны қолдану // *Наука и Здравоохранение*. 2024. Т.26 (6). С. 219-224. doi 10.34689/SH.2024.26.6.024

Introduction

Despite the great achievements of modern pediatric pulmonary surgery, the treatment of pulmonary pleural forms (PPF) of acute bacterial destructive pneumonia (ABDP) is still a difficult and complex task [6,7].

The urgency of the problem is due to the high percentage of ineffective drainage and sanitation of the pleural cavity, which requires surgical correction (up to 50%) [9] and high mortality rate up to 20% [10-13]. PPF occurs in 26.5-92.0% and is often admitted for urgent reasons to the general pediatric or general surgical department of a district hospital with respiratory failure caused by pyopneumothorax [1].

The issues of choosing the volume and nature of emergency care in acute respiratory failure remain controversial and are often decided by pediatricians, general practitioners or general surgeons. In most cases, to eliminate pyopneumothorax, conservative treatment is

performed, combined with pleural punctures, or thoracoscopic, hydrosurgical sanitation and treatment of the lungs and pleura with low-frequency ultrasound [8]. Vecherkin V.A. et al. (2019) in a review of foreign literature note the important goals of future researchers on the issues of optimizing conservative and surgical treatment [2].

Materials and methods: There is a method of thoracentesis using a well-known straight trocar, which has a cannula and a stylet with a pointed quadrangular perforating end placed in it [5].

The disadvantage of this device for thoracentesis is the inability, due to the straight stylet, to correctly install the drainage tube along the chest in the apical direction. Also, when trying, especially when moving the trocar upward to correctly install the drainage tube, the ribs and surrounding tissues are injured. When performing manipulation with such a trocar, the drainage tube is often bent and the pleural cavity is poorly drained, which often requires

reinstallation. The well-known straight trocar perforator has a quadrangular stabbing profile. The disadvantage of the latter is the quadrangular cutting surface of the stylet, which during manipulation injures the vessels and surrounding tissues, causing bleeding and swelling of the soft tissues. Due to crushing of soft tissues, it is often necessary to apply multiple sutures, leading to a rough cosmetic effect.

Results

The purpose of the utility model was to perform thoracentesis with a device that facilitates the correct installation of the drainage tube along the chest in the apical direction and effectively drains the pleural cavity. Also, the

device must have the property of reducing trauma and the time required to perform the manipulation.

The essence of the technical solution of the utility model was achieved through the use of a trocar designed by us[3]. The latter consists of a conulle and a stylet, respectively, having an arched bend with an angle of 90 degrees with a handle, and the perforating end of the stylet has a conical shape [4].

The diagram of the utility model is illustrated by a drawing, where:

Figure 1 shows a device that consists of an arched cone - 1, a stylet with a handle - 2 with a pointed cutting cone-shaped perforator - 3.

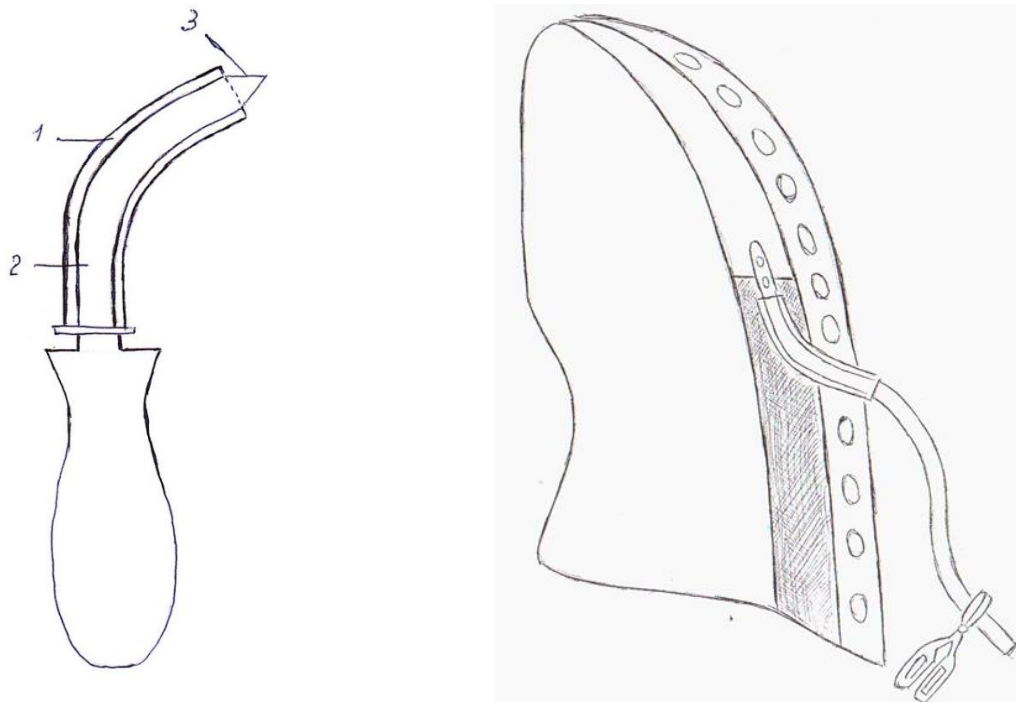


Figure 1. Device for drainage of the pleural cavity.

The device is used as follows. With the patient in a sitting position, after treating the surgical field and the surgeon's hands with an aseptic solution under local anesthesia and using 0.25% or 0.5% novocaine solution, a skin incision up to 1 cm long is made in the 8th intercostal space on the left, 7th intercostal space on the right between the scapular and mid-axillary lines. A trocar corresponding to the size of the inserted tube is inserted. After which the instrument pierces the chest. In this case, the handle is directed upward. After piercing the chest wall, the tip of the trocar is directed along the chest in the apical direction. The stylet is removed and a drainage tube is inserted through the cannula to the required length. The trocar is removed, the tube is sutured to the skin with one interrupted suture. The end of the rubber tube is lowered into a vessel with an antiseptic solution.

The instrument is simple, and the manipulation is easily understood by doctors who do not have surgical training. The use of the invention provides effective drainage of the pleural cavity in case of pyopneumothorax in children.

Discussion and conclusion

The set of significant distinctive features of the device for thoracentesis is that, due to the arcuate bend of the cone with an angle of 90°, it is easy to correctly install the drainage tube along the chest in the apical direction,

ensuring effective drainage and sanitation of the pleural cavity in case of pyopneumothorax in children. And the sharp cone-shaped perforator of the stylet, reducing trauma, prevents bleeding and swelling of soft tissues. In general, the device allows to reduce the time of surgery, which improves treatment outcomes and length of stay of the patient in the hospital.

The technical prostate of thoracentesis with a new device and its effectiveness for drainage and sanitation of the pleural cavity in case of pyopneumothorax in children make possible its widest use in any hospital, at any stage in the provision of emergency medical care by pediatricians, general practitioners and surgeons. Also, complete drainage and sanitation of the pleural cavity prevents destruction of the structure of the lungs and pleura and thereby improves treatment outcomes.

According to the proposed device, 27 patients with pyopneumothorax drainage of the pleural cavity were performed. The average duration of the operation is 10-12 minutes. After drainage of the pleural cavity, all patients experienced a decrease in shortness of breath, symptoms of intoxication and an improvement in their general condition. By the end of 1-2 days, the patients did not complain of pain in the area after the surgical wound and complete straightening of the lung tissue was noted.

Duration of drainage until the release of pus and air from the pleural cavity ceases. The drainage tube was removed in 26 patients on days 7-9, and in one patient with a bronchial fistula on days 18. The latter had suppuration of the wound in the area where the drainage tube was placed.

Clinical case:

Patient: K., 2 years old, medical history No. 15464

Clinical diagnosis: Community-acquired acute destructive pneumonia on the right, acute course, severe severity. Pyothorax on the right. Respiratory insufficiency 2-3 degree.

Concomitant diagnosis: DIC syndrome. Posthemorrhagic anemia. Complaints upon admission: weakness, lethargy, shortness of breath, difficulty breathing, severe pallor of the skin, increased body temperature, decreased appetite.

An.morbi: According to the mother, the child has been sick since 12/06/13, it began with catarrhal symptoms, a rise in body temperature to 38.5 C. He received symptomatic treatment. In dynamics, the cough intensified, vomiting, weakness, loss of appetite, thirst, 3 days of high temperature 37.2° -38.5°. With an increase in symptoms of intoxication and shortness of breath, they were taken by ambulance to the Venera UMC. According to the mother, the child was admitted to the Venera UMC on December 9, 2013 in serious condition, received inpatient treatment with Diagnosis Community-acquired focal confluent pneumonia, acute course, severe, complicated by exudative pleurisy.

Respiratory insufficiency 2 degree, neurotoxicosis. Although massive antibacterial therapy, a sharp deterioration of the patient was noted with an increase in the symptoms of acute respiratory failure, and he was taken to the Semy Children's Surgical Department.

The general condition of the child upon admission is extremely serious, due to respiratory failure. Consciousness is soporous. Reduced nutrition, subcutaneous tissue is poorly developed. The skin is pale cyanotic, dry, the facial features are pointed, there are traces of numerous venipunctures in the elbow on the right, left, hands, and ankles on the legs. Heart sounds are muffled, rhythm is correct, tachycardia. Heart rate-150 per minute. A/D-80/50 mmHg. SpO₂-92%. The tongue is thickly coated with white coating. The belly is swollen and soft. The liver protrudes from under the edge of the costal arch by 3.0 cm, the edges are rounded. The kidneys are not palpable, the spleen is not enlarged. There was no stool, there was urine through a catheter - it was installed at the Venera UMC.

St.localis: Difficulty breathing, flaring of the wings of the nose. The act of breathing involves auxiliary muscles, retraction of the lower part of the chest. Cyanosis of the nasolabial triangle. The chest is barrel-shaped. The right half of the chest lags behind in the act of breathing compared to the left half. Percussion above the lungs is a clear pulmonary sound on the left, sharp dullness on the right. Auscultation over the lungs: weakened breathing on the left, not audible on the right. Wheezing is dry. Body temperature 37.5°C, HR-64 per min.

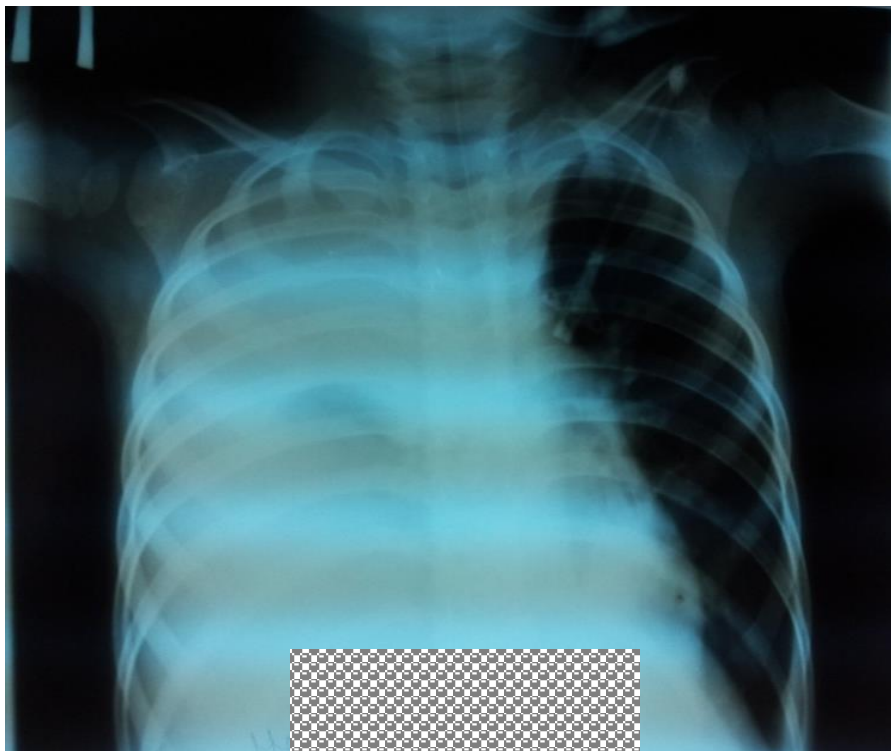


Figure. 2 X-ray of the chest.

X-ray of the chest organs dated December 12, 2013 No. 824 reveals a total homogeneous intense darkening of the right pulmonary field, where the contours of the pulmonary pattern, the right atrium and the dome of the diaphragm are not differentiated. Some flotation of the mediastinum to the left. The left pulmonary field is highly transparent, the

pulmonary pattern on the left is depleted. Conclusion: right-sided tension pyothorax (Figure 2).

Treatment carried out:

A pleural puncture was performed at the State Medical Center on December 12, 2013. 09:40 - 170 ml of cloudy hemorrhagic fluid was received. An operation was

performed - thoracentesis on the right using a trocar developed by us on December 12, 2013.

Under local anesthesia with a 1% solution of 5 ml of novocaine, thoracentesis was performed along the posterior

axillary line, in the 7th intercostal space. The drainage tube was easily installed vertically. About 130 ml of cloudy liquid was released. Stitches on the wound. On the control radiograph, the condition of the lung tissue is as follows:

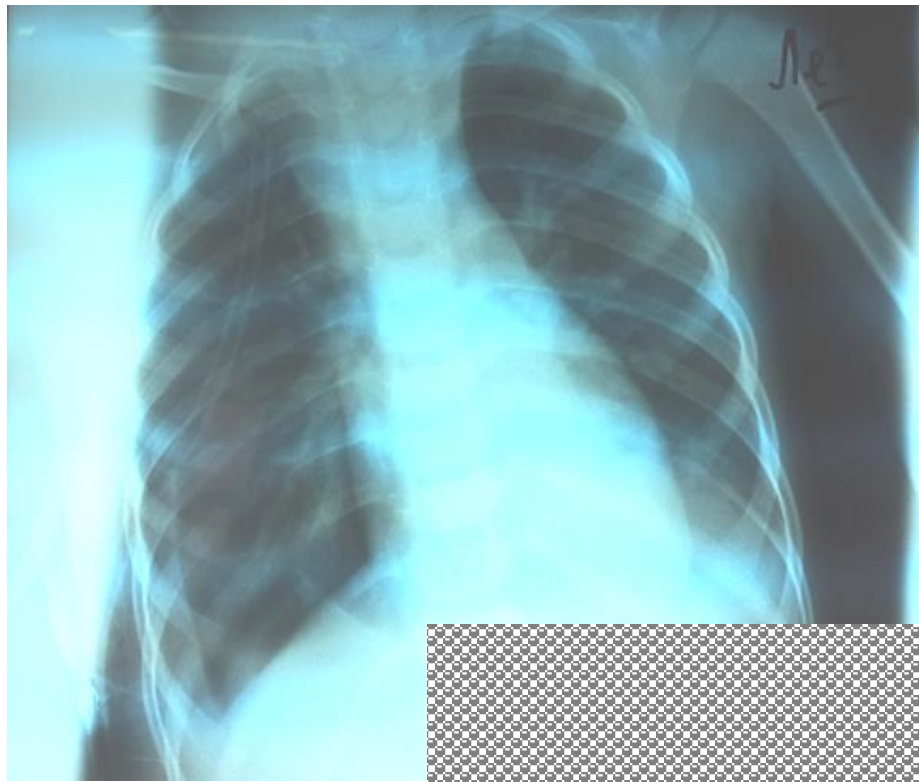


Figure 3. X-ray of the chest.

X-ray of the chest organs dated December 12, 2013 No. 9518 reveals satisfactory re-expansion of the lung tissue, a small amount of fluid is detected paracostally on the right, subcutaneous emphysema on the right

(Figure 3). The shadow of the mediastinum is somewhat expanded, the pulmonary pattern is enriched, the roots are strengthened. The heart contours are clear in places.

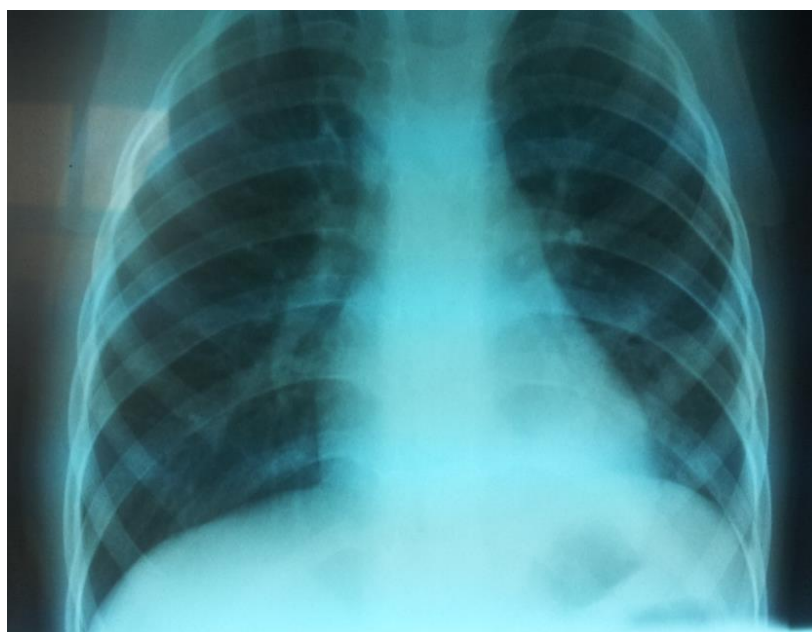


Figure 4. X-ray of the chest.

X-ray of the chest organs dated 12/19/13 No. 9684 reveals positive dynamics in the lungs without focal and infiltrative shadows, the pulmonary pattern is enhanced, the

roots of the lungs have little structure, the sinuses are free, the dome of the diaphragm is smooth - signs of bronchitis (Figure 4).

As a result of treatment, the condition gradually improved.

On a chest x-ray dated December 19, 2013, the lungs were fully expanded and the drainage tube was removed (figure 4). On December 23, 2013, he was discharged home with recovery.

Conclusion: The use of the method ensures effective drainage of the pleural cavity and straightening of the compromised lung in case of pyopneumothorax in children, which prevents the formation of encysted cavities and fibrinous cords requiring surgical correction and minimizes surgical trauma, which allows reducing the length of the patient's stay in the hospital. The ease of performing thoracentesis with the new device makes it possible for its widest use in emergency medical care by pediatricians, general practitioners and surgeons in any setting.

Authors' contributions. All authors took equal part in writing this article.

Conflict of interest – not declared.

This material has not been previously submitted for publication in other publications and is not under consideration by other publishers.

There was no funding from outside organizations or medical offices during this work.

Funding was not provided.

Literature:

1. Барова Н.К. Оптимизация хирургического лечения легочно-плевральных форм острой деструктивной пневмонии у детей. Диссерт. канд. дис. Ростов на Дону, 2018. – 48с.

2. Вечеркин В.А., Тома Д., Птицын В.А., Коряшкин П.В. Деструктивные пневмонии у детей. Росс. вестник детской хирургии, анестезиологии и реаниматологии, 2019. 9(3):108-115.

3. Месова А.М., Санбаев М. Патент полезной модели РК №97674. опуб.15.05.2017. Бюллетень №9.

4. Санбаев М. Совершенствование способа промывания плевральной полости при эмпиеме плевры у детей. Здравоохранение Казахстана, 1989. №4:73-74.

5. Сергиенко В.И., Петросян И.В., Фручи И.В. Топографическая анатомия и оперативная хирургия. Под ред. РАМН Ю. М. Лопухин М. 2009. Том 1. (рис 1а).

6. Тараканов В.А., Барова Н.К., Шумливая Т. П., с соавт. Современные технологии в диагностике и лечении острой бактериально-деструктивной пневмонии у детей. Росс. Вестник. 2015. №1:50-55

7. Хаспеков Д.В., Ольхова Е.Б., Топилин О.Г., Сафин Д.А., Ткаченко Н.В., Соколов Ю.Ю. Современные методы диагностики и лечения деструктивной пневмоний у детей. Росс.вестник дет, 2015. 5(2):7-12.

8. Chetty K., Thomson A.H. Management of community acquired pneumonia in children. Paediatr. Drugs, 2007. Vol 9. №6: 401-411.

9. de Benedictis F.M., Keren A.B., Chand A.B., Colin A. A., Zar N.J., Bush A. Complicated pneumonia in children Lancet, 2020.396:786-798.

10. Smith M.S., Wasserman G.A., Coleman F.T. Regionally compartmentalized resident memory T cells mediate naturally acquired protection against pneumococcal pneumonia. Mucosal Immunology, 2018. № 11(1):220-235.

11. Spencer D.A., Spencer D.A., Thomas M.F. Necrotizing pneumonia in children. Paediatric Respiratory Reviews, 2014. Vol15. №3:240-245.

12. Taffare L.P. Severe Staphylococcus aureus infection in three pediatric intensive care units: analysis of cases of necrotizing pneumonia. Arch Argent. Pediatr, 2014. Vol.112:163-168.

13. Yu D. Seventeen-year study shows rise in parapneumonic effusion and empyema with hinder treatment failure after chest tube drainage // Acta Paediatrica, 2014. Vol 103. № 1:93-99.

References: [1-7]

1. Barova N.K. *Optimizatsiya khirurgicheskogo lecheniya legochno-plevral'nykh form ostroi destruktivnoi pnevmonii u detei* [Optimization of surgical treatment of pulmonary-pleural forms of acute destructive pneumonia in children]. Dissert. kand.dis. Rostov na Donu, 2018 6. 48p. [in Russian]

2. Vecherkin V.A., Toma D., Ptitsyn V. A., Koryashkin P., V. *Destruktivnye pnevmonii u detei* [Destructive pneumonia in children]. Russian Bulletin of Pediatric Surgery, Anesthesiology and Resuscitation]. *Ross. vestnik detskoj khirurgii, anesteziologii i reanimatologii* [Russian Bulletin of Pediatric Surgery, Anesthesiology and Resuscitation], 2019. 9 (3): 108-115.]. 2019.9 (3):108-115. 6 [in Russian]

3. Messova A.M., Sanbaev M. *Patent poleznoi modeli RK* [Patent of utility model of the Republic of Kazakhstan] №97674. opub.15.05.2017. Byul'.№9.

4. Sanbaev M. *Sovershenstvovanie sposoba promyvaniya plevral'noj polosti pri empieme plevry u detei* [Improving the method of washing the pleural cavity in empyema in children]. *Zdravookhranenie Kazakhstana* [Healthcare of Kazakhstan], 1989. №4:73-74 6 [in Russian]

5. Sergienko V.I., Petrosyan I.V., Fruchi I.V. *Topograficheskaya anatomiya i operativnaya khirurgiya* [Topographic anatomy and operative surgery.]. Pod red. RAMN Yu.M. Lopuhin, M, 2009.Tom1. (ris1a). 6 [in Russian]

6. Tarakanov V.A., Barova N.K., Shumliyaya T.P. et al. *Sovremennye tehnologii v diagnostike i lechenii ostroi bakterial'no-destruktivnoi pnevmonii u detei* [Modern technologies in diagnostics and treatment of acute bacterial destructive pneumonia in children]. *Ross. Vestnik* [Ross. Bulletin]. 2015, №1: 50-55. [in Russian]

7. Khaspekov D.V., Ol'khova E.B., Topilin O.G., Safin D.A., Tkachenko N.V., Sokolov Yu.Yu. *Sovremennye metody diagnostiki i lecheniya destruktivnoi pnevmonii u detei* [Modern methods of diagnostics and treatment of destructive pneumonia in children]. *Ross. vestnik* [Ross. Vestnik det], 2015. 5(2):7-12. [in Russian]

Corresponding author:

Messova Assylzhan - associated professor of child diseases department, Astana medical university;

Address: Republic of Kazakhstan, Astana city, Turkistan St., 8/1, flat 68.

E-mail: assylzhan2006@mail.ru,

Phone: 8 777-213-83-07