

Received: 03 February 2021 / Accepted: 16 May 2021 / Published online: 30 June 2021

DOI 10.34689/SH.2020.22.3.020

УДК 616.12-008.318.1

## SUBSTRATE MODIFICATION OF RIGHT ATRIUM IN A PATIENT WITH SCAR-RELATED ATRIAL FLUTTER

**Abay Bakytzhanuly<sup>1</sup>**, <https://orcid.org/0000-0001-7816-7327>

**Bakytzhan Bimbetov<sup>2</sup>**, <https://orcid.org/0000-0002-8309-0897>

**Omirbek Nuralinov<sup>1</sup>, Zhanasyul Suleymen<sup>1</sup>,**

**Ayan Abdrakhmanov<sup>1</sup>**, <https://orcid.org/0000-0001-6315-5016>

<sup>1</sup> Interventional arrhythmology department, JSC “National Scientific Cardiac Surgery Center”, Nur-Sultan, Republic of Kazakhstan;

<sup>2</sup> RSE “Hospital of the Medical Center” of the Department of Affairs President of the Republic of Kazakhstan, Nur-Sultan, Republic of Kazakhstan.

### Abstract

Mapping multiple atrial flutter re-entry circles after previous cryoballoon pulmonary vein isolations and multiple radiofrequency ablations can be challenging even for experienced specialists. Inappropriate radiofrequency ablation leads to scar-related electrical changes in the left and the right atria. We present a case of fractionated electrograms of the right atrium in a patient with previous radiofrequency ablations due to atrial fibrillation and atypical atrial flutter. PentaRay mapping catheter was used to identify the mechanisms of tachycardia precisely and to map fractionated electrograms.

**Key words:** atypical atrial flutter, atrial fibrillation, right atrium substrate modification, catheter ablation, 3D mapping.

### Резюме

## МОДИФИКАЦИЯ СУБСТРАТА ПРАВОГО ПРЕДСЕРДИЯ У ПАЦИЕНТА С ИНЦИЗИОННЫМ ТРЕПЕТАНИЕМ ПРЕДСЕРДИЙ

**Абай Бакытжанұлы<sup>1</sup>**, <https://orcid.org/0000-0001-7816-7327>

**Бакытжан Бимбетов<sup>2</sup>**, <https://orcid.org/0000-0002-8309-0897>

**Омирбек Нуралинов<sup>1</sup>, Жанасыл Сулеймен<sup>1</sup>,**

**Аян Абдрахманов<sup>1</sup>**, <https://orcid.org/0000-0001-6315-5016>

<sup>1</sup> Отделение интервенционной аритмологии, АО “Национальный Научный Кардиохирургический Центр”, г. Нур-Султан, Республика Казахстан;

<sup>2</sup> РМК “Больница Медицинского Центра” Управления Делами Президента Республики Казахстан, г. Нур-Султан, Республика Казахстан.

Картирование атипичного трепетания предсердий с множеством ре-энтри циклов после ранее проведенной криобаллонной изоляции устьев легочных вен и множество радиочастотных абляций может быть достаточно сложным даже для опытных хирургов. Необоснованная радиочастотная абляция приводит к рубцовым изменениям в левом и правом предсердиях. Описывается клинический случай с фракционированием электрограмм правого предсердия у пациента с ранее проведенной радиочастотной абляцией при фибрилляции и атипичного трепетания предсердий. Картирующий катетер PentaRay был использован для точного определения механизмов тахикардии и картирования фракционированных электрограмм.

**Ключевые слова:** атипичное трепетание предсердий, фибрилляция предсердий, субстратная модификация правого предсердия, катетерная абляция, 3D картирование.

### Түйіндеме

## ИНЦИЗИОНДЫ ЖҮРЕКШЕ ДІРІЛІ БАР НАУҚАСТА ОҢ ЖҮРЕКШЕ СУБСТРАТ МОДИФИКАЦИЯСЫ

**Абай Бакытжанұлы<sup>1</sup>**, <https://orcid.org/0000-0001-7816-7327>

**Бакытжан Бимбетов<sup>2</sup>**, <https://orcid.org/0000-0002-8309-0897>

**Өмірбек Нұралинов<sup>1</sup>, Жанасыл Сүлеймен<sup>1</sup>,**

**Аян Абдрахманов<sup>1</sup>**, <https://orcid.org/0000-0001-6315-5016>

<sup>1</sup> Интервенциялық аритмология бөлімшесі, АҚ “Ұлттық Ғылыми Кардиохирургия Орталығы”, Нұр-Сұлтан қ., Қазақстан Республикасы.

<sup>2</sup> РМК «Қазақстан Республикасы Президентінің Іс басқармасы Медициналық орталығының ауруханасы», Нұр-Сұлтан қ., Қазақстан Республикасы

Криобаллонды өкпе көк-тамырларының изоляциясын және бірнеше рет радиожилікті абляциясы жасалған науқастарда уақыт өте келе көп ре-ентри циклды күрделі атипиялық жүрекше дірілі жиі пайда болады. Бұл атипиялық жүрекше дірілінің картасын салу және механизмін анықтау хирургтарға қиын болуы мүмкін. Қажетсіз радиожилікті абляциялар оң және сол жүрекшелерде дәнекер тінінің түзілуіне алып келеді. Мақалада бірнеше рет радиожилікті абляцияға ұшыраған және өкпе көк-тамырларының криоабляциясы жасалған науқастың оң жүрекше электрограммасының фракцияланған клиникалық жағдайы сипатталған. Жүрекше картасын салу үшін және аритмия механизмін нақтырақ білу үшін арнайы PentaRay диагностикалық электрод қолданылды.

**Түйінді сөздер:** атипиялық жүрекше дірілі, жүрекше жыпылығы, оң жүрекшенің субстратты модификациясы, катетерлі абляция, 3D карта.

#### Библиографическая ссылка:

Bakytzhanuly A., Bimbetov B., Nuralinov O., Suleymen Zh., Abdрахmanov A. Substrate modification of right atrium in a patient with scar-related atrial flutter // *Nauka i Zdravookhranenie* [Science & Healthcare]. 2021, (Vol.23) 3, pp. 165-170. doi 10.34689/SH.2021.23.3.020

Бақытжанұлы А., Бимбетов Б., Нұралинов О., Сүлеймен Ж., Абдрахманов А. Модификация субстрата правого предсердия у пациента с инцизионным трепетанием предсердий // *Наука и Здравоохранение*. 2021. 3(Т.23). С. 165-170. doi 10.34689/SH.2021.23.3.020

Бақытжанұлы А., Бимбетов Б., Нұралинов О., Сүлеймен Ж., Абдрахманов А. Инцизионды жүрекше дірілі бар науқаста оң жүрекше субстрат модификациясы // *Ғылым және Денсаулық сақтау*. 2021. 3 (Т.23). Б. 165-170. doi 10.34689/SH.2021.23.3.020

#### Introduction

Atrial fibrillation (AF) is a widespread heart rhythm disorder and leads to left atrial thrombosis. The treatment of AF is complex and begins from the prevention of thromboembolic complications by administering anticoagulants. Point-by-point radiofrequency ablation (RFA) and cryoballoon isolation of the pulmonary veins (PVs) remain the most common treatment for symptomatic and drug-resistant AF [1]. However, after the interventional procedures, the recurrence of AF or onset of other atrial tachycardia and atypical atrial flutter (AFL) may be observed [2]. The successful RFA depends on different factors. One of them is the complexity of the PVs' anatomy, especially after a series of cardio surgical and interventional procedures. The other one is an accurate and quick mapping with the multipolar diagnostic catheters in combination with navigation systems. Therefore, in parallel with the increasing amount of catheter ablation, the new catheters have been designed. The Penta Ray high-density mapping diagnostic catheter (Biosense Webster, California, USA (2019)) is one of these new catheter generations. In this clinical case, we demonstrate the use of Penta Ray high-density mapping diagnostic catheter for fast and precise electroanatomical mapping to understand the origins of arrhythmias.

#### Clinical case

A 59-year-old male was presented to our clinic, JSC "National Scientific Cardiac Surgery Center", Nur-Sultan, with 9 years of AF history. Previously, he underwent pulmonary vein isolation (PVI), PVs re-isolation, additional radiofrequency linear lesions on the anterior wall, and the left atrium (LA) roof during different hospitalizations. The patient took rivaroxaban (Bayer, AG, Germany) 20 mg per day for 3 months before the current procedure. Hypertension, obesity and diabetes were diagnosed for a long time. Glucose analysis and hypertension were compensated previously. Before index hospitalization

patient reduced his weight from 112 to 95 kilograms and decreased body mass index to 32 kg/m<sup>2</sup>. The patient was observed in 4 days and was prepared to perform an electrophysiology study and perform RFA. Before the procedure patient signed informed consent for the surgery and agreed to be published without personal details.

According to multiple RFA before the index procedure, we decided to use Carto 3 navigation system (Biosense Webster, California, USA) for a clear understanding of atrial arrhythmias mechanisms. The patient was connected to 6 magnetic patches and was initialized. A standard femoral vein approach was used to insert into the heart the diagnostic and ablation catheters. A decapolar diagnostic catheter (Biosense Webster, California, USA) was positioned into the coronary sinus under fluoroscopy guidance via the right femoral vein. Atypical AFL with tachycardia circle length 288ms and early distal electrode activation was identified. Coronary sinus distal electrodes were entrained and the post-pacing interval was 301ms. Thus, it was decided to start by checking previous RFA lines in LA. A single transseptal puncture via the right femoral vein was performed under the fluoroscopy guidance with an 8.5-Fr SL-1 sheath (Abbott) by means of the modified Brockenbrough technique (BRK-1, Abbott). Once transseptal access was obtained, heparin boluses were repeatedly administered to maintain the activated clotting time between 300 and 350 seconds. The Penta Ray high-density mapping diagnostic catheter replaced the transseptal needle to create a 3D electroanatomical map of LA. A high-density bipolar mapping with potential detection parameters of 0.2-0.5 mV was done. A bipolar LA map revealed the gap in the right superior PVI, absence of blocks in anterior (Fig. 1.) and roof RFA lines, fractionated electrograms in the posterior wall. We performed right superior PV re-isolation, radiofrequency linear applications on the anterior wall during which the tachycardia circle length changed to 235ms. The Post-pacing interval showed

249ms on the roof of LA. Linear RFA of the roof which followed by fractionated electrograms modifications on the posterior wall of LA (Fig.2) changed the tachycardia circle length to 227ms with still distal electrodes earliest activation

on decapolar catheter. Another activation map was created and revealed zones of the critical isthmus in the area of carina of left PVs with post-pacing interval 234ms. (Fig.3).

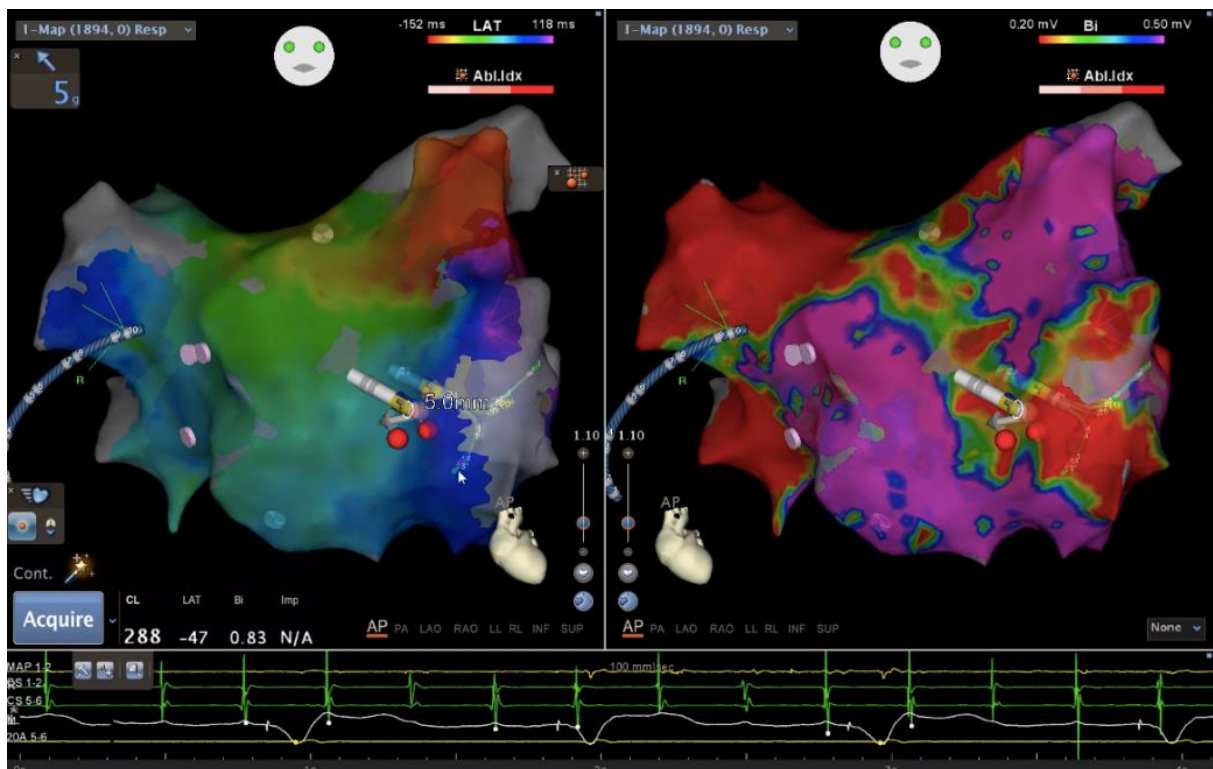


Figure 1. 3D electroanatomical map of LA.

Left panel demonstrates absence of previous linear RFA blocks. Tachycardia circle length 288ms.

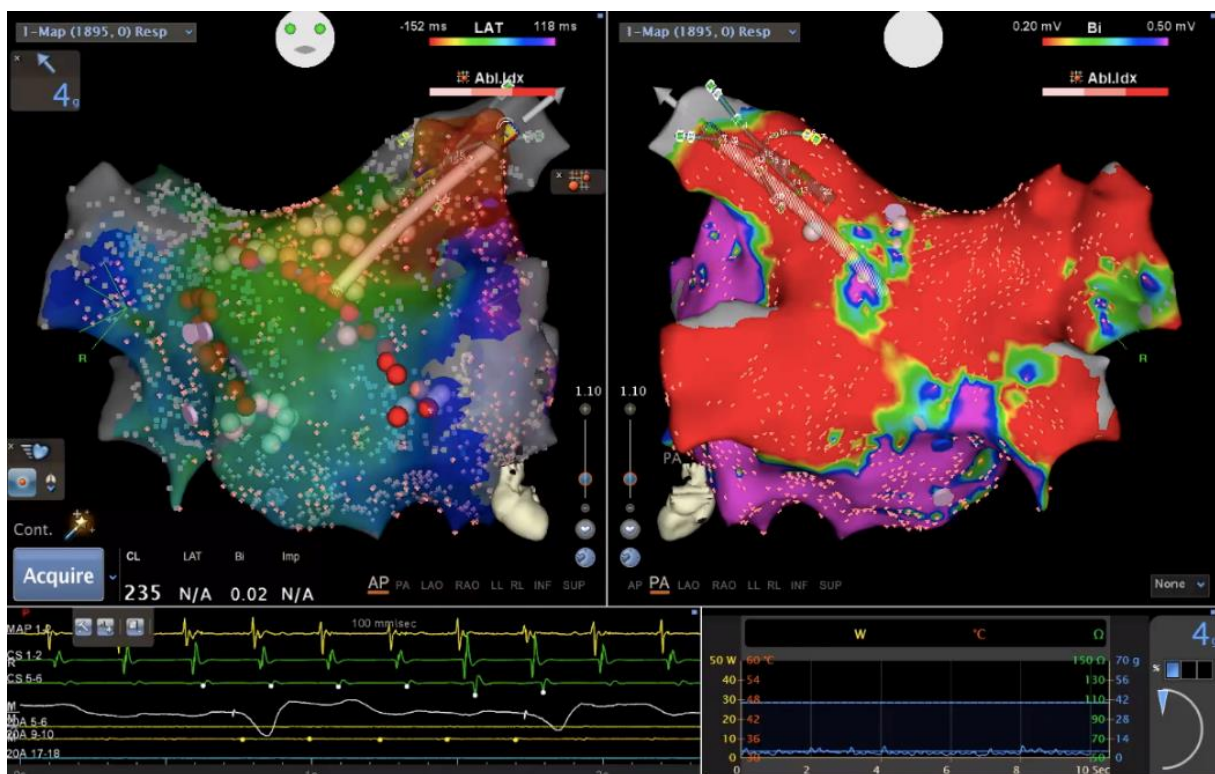
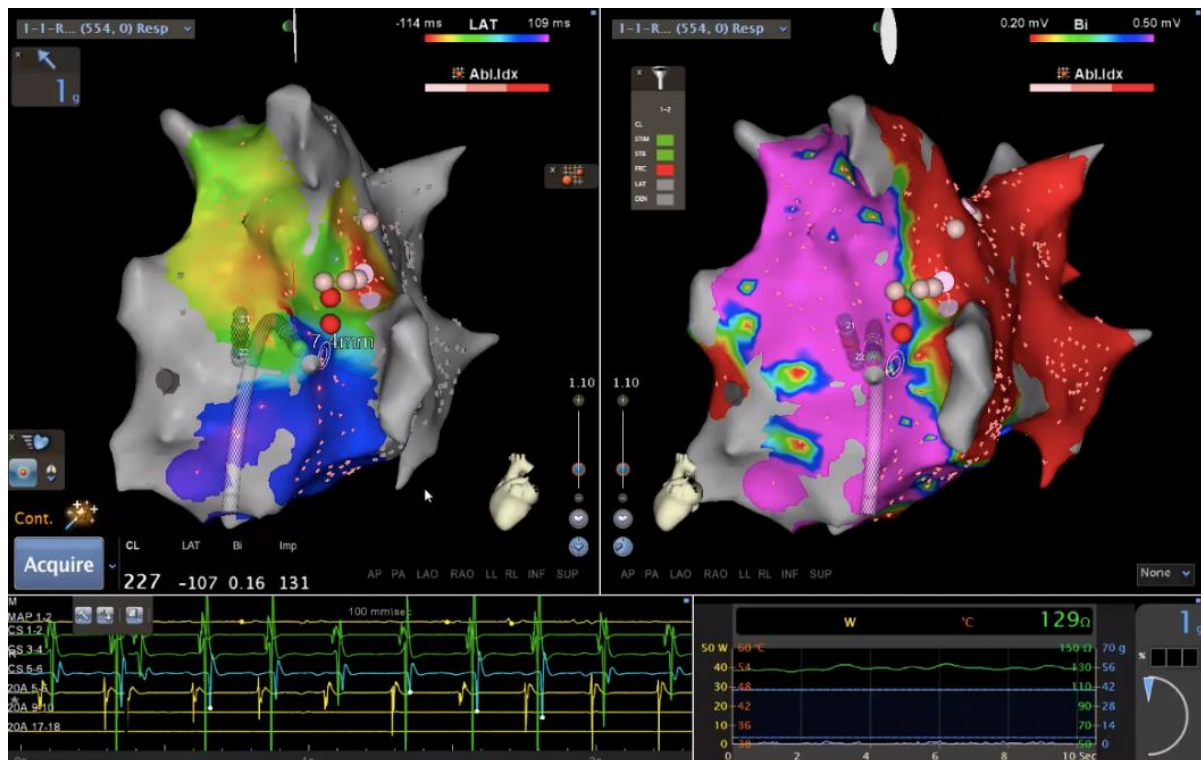


Figure 2. Linear RFA of anterior and superior LA walls, re-isolation of right superior PV and substrate modification of posterior wall. Red dots are RFA lesions. Tachycardia circle length 235ms.



**Figure 3. Linear RFA of left PVs' carina area.**

Red dots are RFA lesions. Tachycardia circle length 227ms.

Linear RFA in this area terminated the tachycardia. The CLOSE protocol [5] was used during the LA radiofrequency ablation procedure. The Thermo Cool Smart Touch (Biosense Webster, California, USA (2018)) ablation catheter was used with parameters: P- 35 V, temperature 46 -500C, impedance 103-128 Ohms, ablation catheter targeting inter-lesion distance  $\leq 6$ mm, ablation index in posterior and inferior walls of LA  $>400$ , ablation index in superior and anterior walls of LA  $>500$  (according to CLOSE protocol).

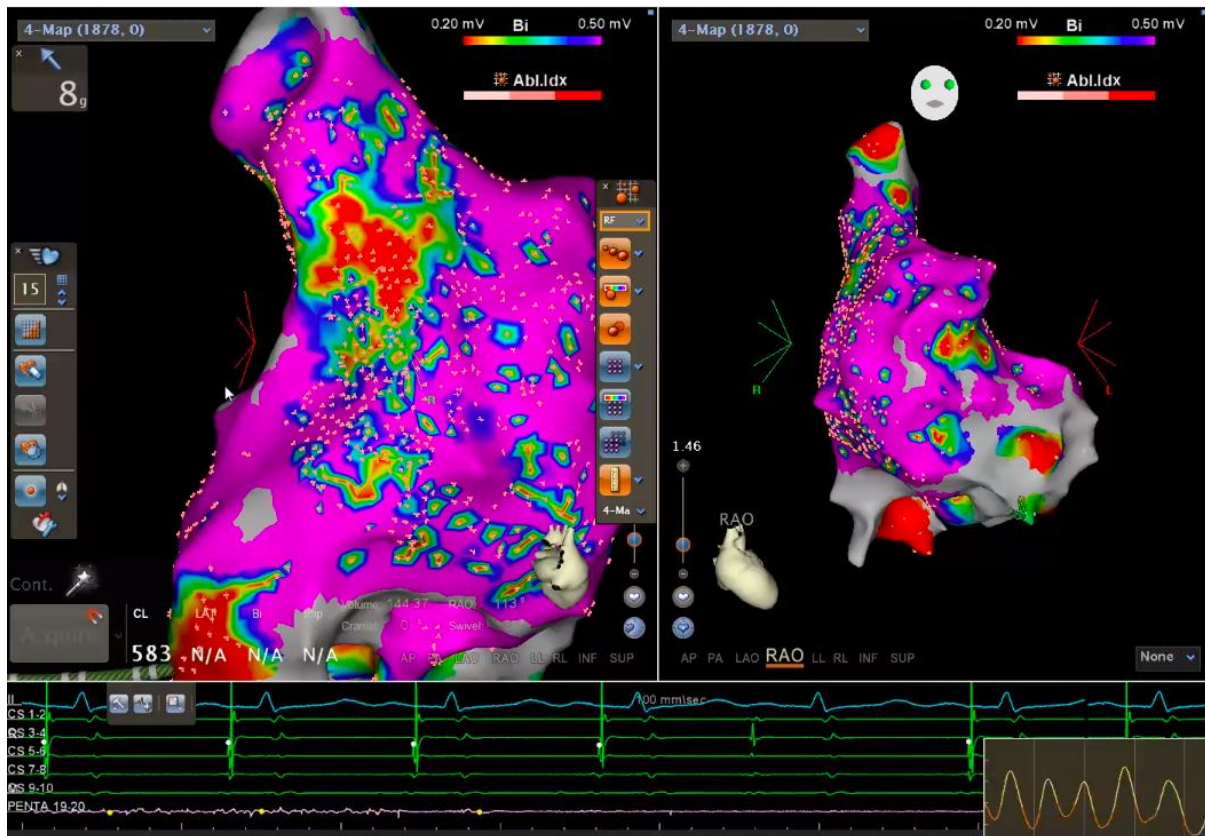
Control electrophysiological study was performed to check the sustained block in radiofrequency lines and the inducibility of other atrial arrhythmias. Burst stimulation induced typical AFL (tachycardia circle length 250ms) with early activation of proximal coronary sinus electrodes according to decapolar diagnostic catheter. Penta Ray high-density mapping diagnostic catheter positioned in the right atrium (RA), the electroanatomical map was created. Entrainment with distal electrodes of ablation catheter showed post-pacing interval 268ms on the cavotricuspid isthmus which defines the isthmus dependent AFL and lead to its' RFA with bidirectional isthmus block achievement (155ms and 162ms) and termination of atrial arrhythmia. The ablation parameters: P- 40 V, ablation index  $>550$ , temperature 45-500C, impedance 100-155 Ohms. A control bipolar mapping revealed fractionated electrograms of the RA lateral wall. The fractionated electrograms usually initiate additional arrhythmias (Fig.4).

We identified zones of phrenic nerve by stimulation, tagged them as yellow dots, and performed a modification of fractionated electrograms to prevent a patient from the initiation of other atrial tachycardia. The ablation parameters were the same with the target ablation index  $>400$ . The new electroanatomical map of RA used to check the efficacy of substrate modification of fractionated electrograms and the

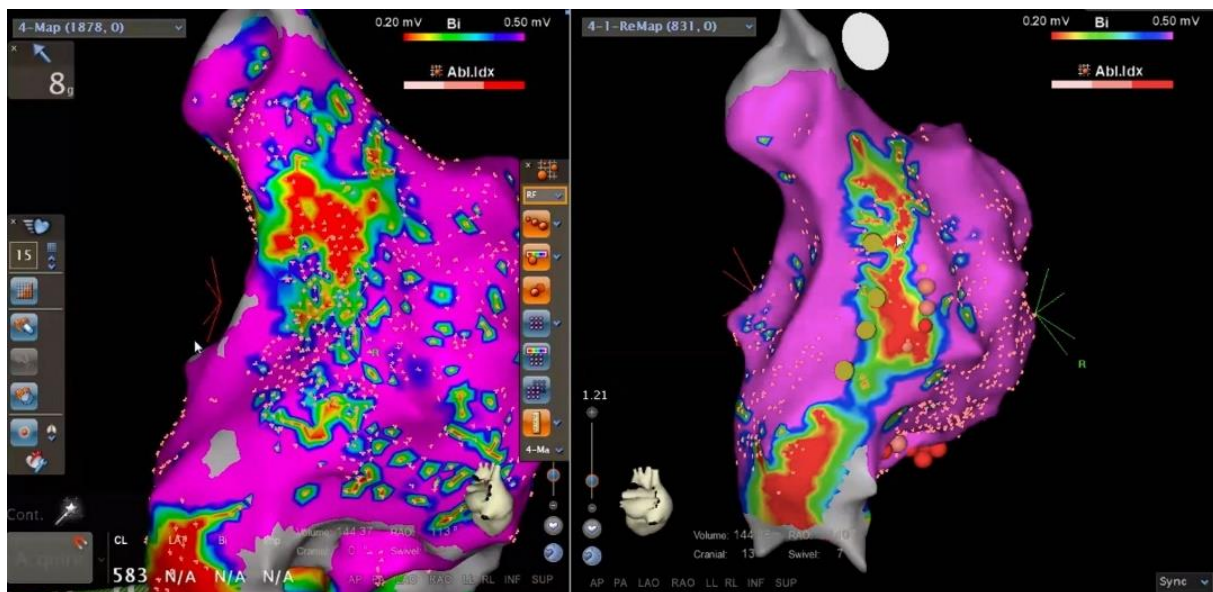
bipolar map showed the homogenization of potentials and visualization of a single block line in the lateral wall of the right atrium (Fig.5, right panel).

#### Discussion

This case demonstrates multiple re-entry atrial tachycardia in a patient after several previous RFA. According to activation and bipolar mapping, we performed re-isolation of right superior PV, linear RFA of anterior and superior walls, and in the area of left PVs' carina. Additionally, substrate modification of the LA posterior wall was performed. Afterward, control bipolar mapping showed the homogenization of the posterior wall, sustained radiofrequency lines block on superior and anterior walls, which decreases the probability of atrial arrhythmia recurrence. Burst stimulation performed to check other mechanisms of atrial arrhythmias. Induced cavotricuspid isthmus dependent AFL terminated by linear RFA reaching bidirectional isthmus block. Thus, we terminated atypical AFL with multiple tachycardia circle lengths, 288ms, 235ms, 227ms, and 250ms, respectively. Control RA bipolar mapping identified fractionated electrograms as in LA posterior wall. As in LA in RA the fractionated electrograms might cause re-entry tachycardia [3]. Atypically, this case with RA fractionated electrograms with no cardiac surgery incision in the history of the patient. The relationship between the extent of fibrosis and AF or AFL is unclear but could be explained in several ways. Widespread fibrotic processes in the atria may lead to persistent AF or a consequence of the long-standing AF process [6]. AF and AFL's RA mechanisms were experimentally demonstrated in a rat model with an underlying substrate involving RA fibrosis and conduction abnormalities [4]. The role of RA fibrosis in AF and AFL in patients with no cardiac surgery history is still uncertain and needs further studies.



**Figure 4. 3D electroanatomical map of RA with identified fractionated electrograms on the RA free wall.**  
Clearly visualized the non-homogeneous electrograms described by multiple red and green colors on RA free wall.



**Figure 5. 3D electroanatomical map after radiofrequency substrate modification of RA free wall.**

Right panel shows more homogenous bipolar map of RA with clear RFA line in RA free wall.

Red dots are RFA lesions, yellow dots are phrenic nerve localization.

### Conclusion

The mechanisms of micro re-entry arrhythmias in the majority of cases depend on the presence of fibrotic remodeling of the heart. Fibrotic remodeling appears either in post-cardiac surgery periods or in elder patients. Cardiac surgery procedures mean performing several incisions which may cause atypical AFL or in fewer cases cause typical AFL. AFL is more persistent for anti-arrhythmic drugs

and decompensates the patients' condition more rapidly compared with AF. Thus, catheter-based treatment of atypical atrial flutter or typical atrial flutter after cardiac surgery is effective. Incisions after surgery and fibrotic remodeling of the heart maintain continuous atrial arrhythmias. The fractionated electrograms of the left atrium are more examined than RA fractionated electrograms. It can be explained by the widespread catheter ablation due

to the AF. 2% and more population of the Earth suffer from AF and still one of the discussed items of the scientific world. The RFA in AF is performed point by point isolation of PVs and additional linear ablations performed in LA if needed. The LA fibrotic processes maintain the AF and atypical AF. According to rear cases of RA mechanisms of AF, the fibrotic processes in RA are less examined and underestimated. In our opinion, any fibrotic process can cause complex arrhythmias which also lead to the development of more fibrotic changes in the myocardium. This leads to the cause of recurrent atrial arrhythmias, ineffective anti-arrhythmic therapy, and patients decompensation. Complex arrhythmias need complex treatment, the combination of antiarrhythmic drugs, and catheter ablation. Navigation 3D systems and high-density mapping increase the understanding of mechanisms increase the safety and effectiveness of the procedure. The use of multipolar high-density mapping catheters like PentaRay creates more detailed electroanatomical map.

Thus, it decreases the amount of unnecessary radiofrequency applications because each radiofrequency application is the reason for fibrotic tissue development. It is still uncertain the RA mechanisms of AF and needs more studies but multipolar high-density mapping catheters may contribute to understanding complex atrial arrhythmias.

**Вклад авторов:** Все авторы в равной мере принимали участие при подготовке данного материала.

**Конфликт интересов:** Конфликт интересов не заявлен.

**Финансирование.** При проведении данной работы не было финансирования сторонними организациями и медицинскими представительствами.

**Сведения о публикации:** результаты данного случая не были опубликованы ранее в других журналах и не находятся на рассмотрении в других издательствах.

**Data availability** The data underlying this article are available in Figshare, at <https://doi.org/10.6084/m9.figshare.12148416.v1>

#### References:

1. *Andrikopoulos G., Tzeis S., Vardas P.E.* Invasive therapy for atrial fibrillation: recent developments in ablation, navigation and mapping technology // *Heart*. 2011. <http://dx.doi.org/10.1136/hrt.2009.190017>
2. *Calkins H., Hindricks G., Cappato R., et al.* HRS/EHRA/ECAS/APHS/SOLAECE expert consensus statement on catheter and surgical ablation of atrial fibrillation // *Heart Rhythm*. 2017;14(10):e275–e444. <http://doi:10.1016/j.hrthm.2017.05.012>
3. *Hiram R., Naud P., Xiong F., Al-U'datt D., Algalarrondo V., Sirois M.G., Tanguay J.F., Tardif J.C., Nattel S.* Right Atrial Mechanisms of Atrial Fibrillation in a Rat Model of Right Heart Disease // *J Am Coll Cardiol*. 2019 Sep 10;74(10):1332-1347. doi: 10.1016/j.jacc.2019.06.066. PMID: 31488271.
4. *Platonov P.G.* "Atrial fibrosis: an obligatory component of arrhythmia mechanisms in atrial fibrillation?" // *Journal of geriatric cardiology: JGC* vol. 14,4 (2017): 233-237. doi:10.11909/j.issn.1671-5411.2017.04.008
5. *Philips T., Taghji P., El Haddad M., Wolf M., Knecht S., Vandekerckhove Y., Tavernier R., Duytschaever M.* Improving procedural and one-year outcome after contact force-guided pulmonary vein isolation: the role of interlesion distance, ablation index, and contact force variability in the 'CLOSE'-protocol // *Europace*. 2018 Nov 1;20(F1\_3):f419-f427. doi: 10.1093/europace/eux376. PMID: 29315411.
6. *Ting Yung Chang, Li Wei Lo, Abigail Louise D. Te et al.* The importance of extrapulmonary vein triggers and atypical atrial flutter in atrial fibrillation recurrence after cryoablation: Insights from repeat ablation procedures // *J Cardiovasc Electrophysiol*. 2019; 30: 16-24. <http://doi:10.1111/jce.13741>

#### Corresponding Author

**Bakytzhanuly Abay**, interventional arrhythmology department, JSC "National Scientific Cardiac Surgery Center". Nur-Sultan, Republic of Kazakhstan.

**Postal address:** Republic of Kazakhstan, 010000, Nur-Sultan Turan 38 ave.

**Phone number:** +7 701 383 40 96

**E-mail:** bakytzhanuly@gmail.com